

# Calcific Myonecrosis of Tibialis Anterior in a 76-Year-Old Man with Foot Drop

Naresh Kumar Saini<sup>1\*</sup>, Anamendra Sharma<sup>2</sup>

<sup>1</sup> Assistant Professor, Department of Orthopedics, RNT Medical College, Udaipur Rajasthan, India

<sup>2</sup> Senior Professor, Department of Orthopedics, RNT Medical College, Udaipur Rajasthan, India

\*Corresponding author: Naresh Kumar Saini; Department of Orthopedics, RNT Medical College, Udaipur Rajasthan, India. Tel: +91-02942414305, Email: saini.naresh.naresh@gmail.com

Received: 13 July 2023; Revised: 23 August 2023; Accepted: 10 October 2023

## Abstract

**Background:** Calcific myonecrosis is a rare entity that is considered a sequela of chronic compartment syndrome. A fusiform mass with central liquefaction and peripheral calcification replaces the affected muscle unit.

**Case Report:** We are presenting a case of calcific myonecrosis of the tibialis anterior in a 76-year-old man. Although the mass was present for several years, the patient recently developed leg pain and foot drop. After radiological and histopathological diagnosis, patient was treated with surgical excision of the mass.

**Conclusion:** Although calcific myonecrosis is a benign condition, due to the pressure effect on surrounding structures, it may be a source of leg pain and foot drop. Cortical erosion and scalloping of underlying major bone may be reasons for extremity pain. To relieve pain, alleviate pressure effect, and prevent pathological fracture of the underlying bone, complete surgical excision of the lesion is essential.

**Keywords:** Anterior Tibial Muscle; Compartment Syndromes; Dystrophic Calcification; Lower Extremity; Necrosis

**Citation:** Kumar Saini N, Sharma A. **Calcific Myonecrosis of Tibialis Anterior in a 76-Year-Old Man with Foot Drop.** *J Orthop Spine Trauma* 2024; 10(1): 45-7.

## Background

This rare condition predominantly affects muscles of the lower extremity. Etiopathogenesis of calcific myonecrosis is still not fully elucidated. Only a few cases are reported in the literature. Gallie and Thomson first described calcific myonecrosis as a sequela of compartment syndrome (1). It generally presents with a slow-growing mass in the extremity over several years, and patients sometimes recall a history of trauma to the affected extremity (2-5). Pressure effect on the surrounding soft tissue structure by a significantly large mass becomes troublesome to the patient. In this study, we are presenting a case of calcific myonecrosis of the tibialis anterior in a 76-year-old man.

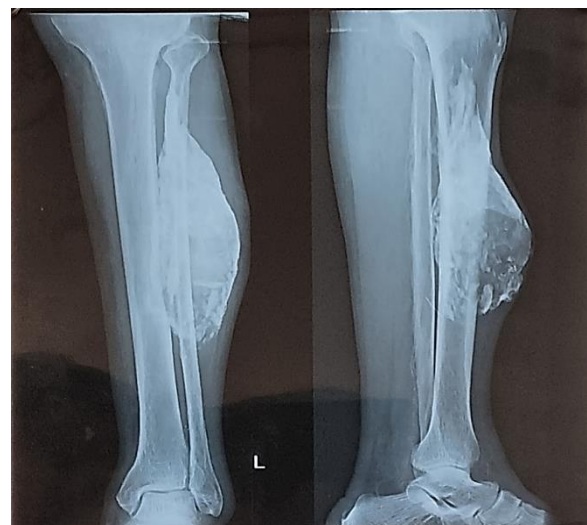
## Case Report

A 76-year-old man presented in the outpatient department with a complaint of pain in his left leg for six months and weakness in his left foot for three months. He had no recent history of significant trauma to his left leg. He recalled a history of trauma by a blunt heavy object to the left leg 35 years back followed by pain and swelling of the left leg. He became asymptomatic after a few weeks except for a small swelling to his left leg. It was very slow-growing and remained asymptomatic till last six months which patient started having pain in the left leg, and developed weakness in the left leg in the last three months.

On examination, the patient was an average-built elderly man and known case of hypertension (HTN) and osteoarthritis of both knees. A non-tender, non-pulsatile swelling measured around 15 × 6 cm with variegated consistency was present over the anterolateral aspect of the left leg. Local temperature was comparable to the contralateral leg. Overlying skin was normal, and not

adhered to the swelling. The swelling was adhered to the underlying bone. The power of ankle dorsiflexion was 3/5, but he had no sensory deficit over the left leg and foot. Distal pulses were palpable and comparable to the right side.

**Investigations:** The complete blood count (CBC), erythrocyte sedimentation rate (ESR), C-reactive protein (CRP), liver function test (LFT), and kidney function test (KFT) were within normal limits. Anteroposterior (AP) and lateral X-rays of the affected leg were done. A fusiform cystic mass with peripheral calcification over the anterolateral aspect of the mid-leg with scalloping of the tibial shaft was present, but there was no pathological fracture and no periosteal reaction of tibia and fibula (Figure 1).



**Figure 1.** Anteroposterior (AP) and lateral X-ray of left leg showing fusiform cystic lesion with peripheral sheet-like calcification and scalloping of the tibia

Copyright © 2024 Tehran University of Medical Sciences. Published by Tehran University of Medical Sciences.



This work is licensed under a Creative Commons Attribution-NonCommercial 4.0 International license (<https://creativecommons.org/licenses/by-nc/4.0/>). Noncommercial uses of the work are permitted, provided the original work is properly cited.

On ultrasonography (USG) examination of the left leg, no vascularity of swelling was visualized. On magnetic resonance imaging (MRI), it was well-defined hypointense lesion with internal hyperintensity in the tibialis anterior muscle on the T2W sequence (measuring 18 × 5.5 × 5 cm). The lesion was causing scalloping in the cortex of the tibia, but no deep extension into the medullary cavity and adjacent soft tissue edema was seen. The lesion was abutting the major neurovascular bundles; however, no encasement was seen (Figure 2).

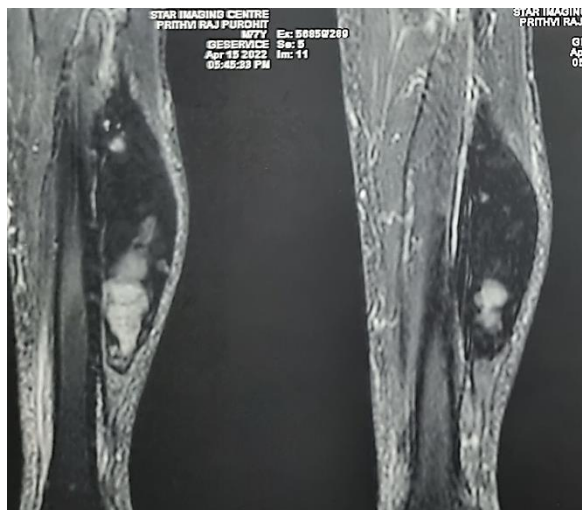


Figure 2. Sagittal sections of T2W magnetic resonance imaging (MRI) of affected leg showing well-defined hypointense lesion with internal hyperintensity in the tibialis anterior muscle

A large exophytic osseous lesion along the anterolateral aspect of the tibia showing circumferential calcification with mineralization from outer to center and central necrotic area was seen on contrast-enhanced computed tomography (CECT) examination of the left leg (Figure 3).

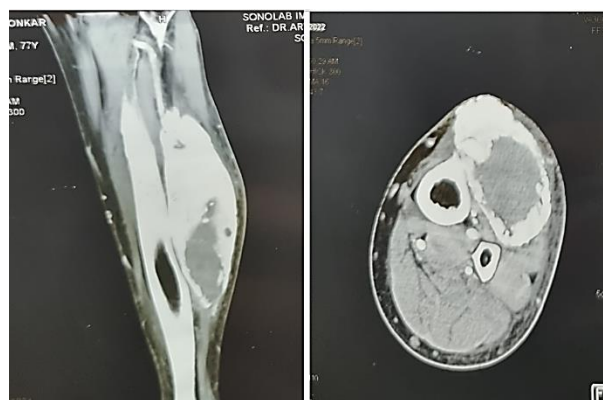


Figure 3. Sagittal and axial cut section of contrast-enhanced computed tomography (CECT) of affected leg showing exophytic lesion in the anterolateral aspect of the leg with circumferential calcification and central necrosis

Histopathological diagnosis was made by core needle biopsy of the lesion which showed multiple necrosed tissue pieces showing dystrophic calcification without any vital cells. Diagnosis of calcific myonecrosis was made by the above clinical and radio-histopathological findings.

**Treatment:** To relieve the pain and pressure effect of the benign mass, surgical excision of calcific myonecrosis

was planned. Written informed consent was taken from the patient. Surgery was performed under spinal anesthesia and a pneumatic tourniquet was used. After sterile preparation of the left leg, a skin incision around 18 to 20 cm was given over the anterolateral aspect of the leg. Intraoperatively, the lesion was a fusiform swelling, 15 × 6 cm in size, and was limited to tibialis anterior muscle unit only. Complete excision of mass and debridement was performed. The underlying anterolateral cortex of the tibia was eroded, but there was no intramedullary extension of the lesion into the tibia and the fibula. Chalky white creamy material came out from the mass (Figure 4).

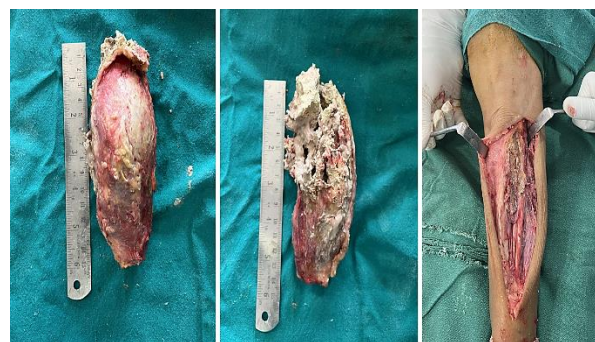


Figure 4. An excised fusiform mass around 15 × 6 cm; chalky white creamy material inside the mass; cortical erosion of anterolateral tibia visualized after excision of mass

A closed wound suction drain was inserted, and the surgical wound was closed in three layers. Closed wound suction was removed after 48 hours; the patient was discharged on the fifth postoperative day. Sutures were removed at two weeks post-op, and the patient kept partial weight bearing till six weeks. There was no leg pain, but ankle dorsiflexion was 3/5 at six weeks follow-up. There were no post-operative complications, like infection and wound dehiscence. At nine months follow-up, there was no recurrence of mass, and ankle dorsiflexion was 4/5 (Figure 5).

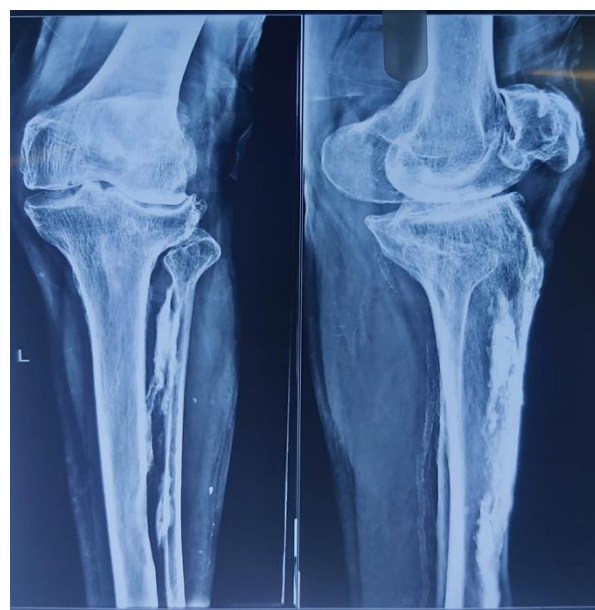

Figure 5. Anteroposterior (AP) and lateral X-ray views of the left leg after nine months postoperatively

## Discussion

Calcific myonecrosis usually develops in lower extremity muscle units, but some cases of the upper extremity are also reported in literature (6-9). Although the etiology of calcific myonecrosis is still not fully described in the literature, it is considered a sequela of compartment syndrome (muscle ischemia and cystic degeneration) following some traumatic event to the extremity (1-5). Jalali and Sharif reported a case of atypical involvement of upper limbs in a 53-year-old poorly controlled diabetic patient (9). Yuenyongviwat et al. presented a case of calcific myonecrosis of leg muscle in a 66-year-old woman as a sequela of snake bite (10).

Although calcific myonecrosis is a benign condition, it may mimic the presentation of sarcoma and myositis ossificans. A thorough clinical work-up, including blood investigations and plain radiograph to computed tomography (CT) scan and/or MRI scan, is essential to rule out conditions other than calcific myonecrosis (4, 11).

Conservative management to complete excision and debridement are described in the literature (2-5). As calcific myonecrosis is a benign condition, a biopsy is only indicated if complete surgical excision is contemplated because secondary infection and chronic fistula formation are reported complications following a biopsy (9, 12).

In our case, we performed a complete surgical excision of the lesion after thorough laboratory and radiological investigations as the patient had leg pain and weakness in the affected foot.

## Conclusion

Although calcific myonecrosis is a benign condition, due to the pressure effect on surrounding structures, it may be a source of leg pain and foot drop. Cortical erosion and scalloping of underlying major bone may be reasons for extremity pain. To relieve pain, alleviate pressure effect, and prevent pathological fracture of the underlying bone, complete surgical excision of the lesion is essential.

## Conflict of Interest

The authors declare no conflict of interest in this study.

## Acknowledgements

This research did not receive any specific grant from funding agencies in the public, commercial, or not-for-profit sectors.

Written informed consent was obtained from the patient for publication of this case report and any accompanying images.

## References

- Gallie WE, Thomson S. Volkmann's ischaemic contracture: Two case reports with identical late sequelae. *Can J Surg.* 1960;3: 164-6. [PubMed: 13826150].
- Okada A, Hatori M, Hosaka M, Watanuki M, Itoi E. Calcific myonecrosis and the role of imaging in the diagnosis: A case report. *Ups J Med Sci.* 2009;114(3):178-83. doi: 10.1080/03009730903016050. [PubMed: 19736609]. [PubMed Central: PMC2852764].
- Jalil R, Roach J, Smith A, Mukundan C. Calcific myonecrosis: A case report and review of the literature. *BMJ Case Rep.* 2012;2012:bcr2012007186. doi: 10.1136/bcr-2012-007186. [PubMed: 23060384]. [PubMed Central: PMC4543734].
- Ukon Y, Tanaka T, Nagata S, Hagizawa H, Imura Y, Tamiya H, et al. Calcific myonecrosis mimicking soft tissue sarcoma: A case report. *Oncol Lett.* 2018;15(5):7909-13. doi: 10.3892/ol.2018.8320. [PubMed: 29731908]. [PubMed Central: PMC5920900].
- Angelini A, Mavrogenis AF, Pagliarini E, Trovarelli G, Fanelli GN, Cappellessio R, et al. Calcific myonecrosis of the leg: A rare entity. *Medicina (Kaunas).* 2019;55(9). doi: 10.3390/medicina55090542. [PubMed: 31466356]. [PubMed Central: PMC6780786].
- Larson RC, Sierra RJ, Sundaram M, Inwards C, Scully SP. Calcific myonecrosis: A unique presentation in the upper extremity. *Skeletal Radiol.* 2004;33(5):306-9. doi: 10.1007/s00256-003-0740-z. [PubMed: 14991247].
- Rynders SD, Boachie-Adjei YD, Gaskin CM, Chhabra AB. Calcific myonecrosis of the upper extremity: Case report. *J Hand Surg Am.* 2012;37(1):130-3. doi: 10.1016/j.jhssa.2011.09.035. [PubMed: 22119606].
- Nagamoto H, Hosaka M, Watanuki M, Shiota Y, Hatori M, Watanabe M, et al. Calcific myonecrosis arising in the bilateral deltoid muscles: A case report. *J Orthop Sci.* 2017;22(4):790-4. doi: 10.1016/j.jos.2015.12.008. [PubMed: 26806333].
- Jalali Z, Sharif SK. Upper-limb diabetic myonecrosis: Atypical presentation of a rare complication. *Am J Case Rep.* 2019;20: 1268-72. doi: 10.12659/AJCR.917030. [PubMed: 31455756]. [PubMed Central: PMC6753662].
- Yuenyongviwat V, Laohawiriyakamol T, Suwanno P, Kanjanapradit K, Tanutit P. Calcific myonecrosis following snake bite: A case report and review of the literature. *J Med Case Rep.* 2014;8:193. doi: 10.1186/1752-1947-8-193. [PubMed: 24934373]. [PubMed Central: PMC4086687].
- Matar HE, Stritch P, Connolly S, Emms N. Calcific myonecrosis: Diagnostic dilemma. *Ann R Coll Surg Engl.* 2018;100(6):e158-e160. doi: 10.1308/rcsann.2018.0077. [PubMed: 29658341]. [PubMed Central: PMC611911].
- Higuchi T, Yamamoto N, Nishida H, Hayashi K, Takeuchi A, Tsuchiya H. Treatment of infected calcific myonecrosis with chronically discharging sinus caused by iatrogenic aspiration: A case report. *Int J Surg Case Rep.* 2022;95:107145. doi: 10.1016/j.ijscr.2022.107145. [PubMed: 35561467]. [PubMed Central: PMC9108875].