

Penrose Drain for Carpal Tunnel Release: A Randomized Controlled Trial

Seyed Houssein Saeed-Banadaky¹, Mazyar Malekzadeh², Abbas Abdoli Tafti^{1,*}

¹ Orthopedist and Hand Surgery Fellowship, Trauma Research Center, Shahid Sadoughi University of Medical Sciences, Yazd, Iran

² Orthopedist, Clinical Research Development Center, Taleghani and Imam Ali Hospitals, Kermanshah, Iran

*Corresponding author: Abbas Abdoli Tafti; Trauma Research Center, Shahid Sadoughi Hospital, Shahid Sadoughi University of Medical Sciences, Yazd, Iran. Tel: +98-3531833252
Email: aabdoli2000@mail.ssu.ac.ir

Received: 08 September 2023; Revised: 17 November 2023; Accepted: 22 December 2023

Abstract

Background: Surgical site hematoma is one of the factors that influence the results of the carpal tunnel release (CTR) and patients' satisfaction; therefore, this study was designed to evaluate the effects of using Penrose drain to reduce the operation site hematoma and improve the results of surgery.

Methods: Patients with a diagnosis of carpal tunnel syndrome (CTS) were randomly divided into intervention and control groups and then were evaluated by pain with the visual analog scale (VAS) and pinch power. The Penrose drain was placed for the intervention group and removed after two days. Three months after surgery, all patients were re-evaluated by VAS and pinch power.

Results: Out of 46 patients, Penrose drains were placed for 21 patients. According to the results, the VAS and pinch power evaluations were better in patients with Penrose drain ($P = 0.001$) but in patients without Penrose drain, only the VAS evaluation results were improved, but a decrease in pinch power was detected.

Conclusion: CTR surgery with or without the Penrose drain decreases pain in patients after three months of operation. CTR with Penrose drain improves pinch power and also decreases the pain, but in patients without Penrose drain, pinch power was reduced after this period.

Keywords: Carpal Tunnel Syndrome; Hematoma; Randomized Controlled Trial

Citation: Saeed-Banadaky SH, Malekzadeh M, Abdoli Tafti A. Penrose Drain for Carpal Tunnel Release: A Randomized Controlled Trial. *J Orthop Spine Trauma* 2024; 10(1): 15-8.

Background

Carpal tunnel syndrome (CTS) results from median nerve compression within the carpal tunnel. It is characterized by pain, numbness, and tingling in the median nerve territory and also decreased grip strength and hand function. CTS is the most common compression mononeuropathy. The annual estimated rate of the disease, which is common in adults, is reported to be 2.2 to 5.4 per 100 women per year and 1.1 to 3 for 100 men, respectively (1-3).

The available treatments are including non-surgical and surgical therapies. Nonsurgical treatments include local steroid injections, non-steroidal anti-inflammatory drugs (NSAIDs), and wrist splints (4).

In most instances, carpal tunnel release (CTR) has satisfactory results, leading to symptom relief, improving patient's function, and returning to work and daily activities (5). However, the result of CTR has not been desirable for some patients, and patient dissatisfaction necessitates re-treatment and imposes additional costs on the patient (6). Several factors cause undesirable surgical results such as inadequate release of the transverse carpal ligament, scar formation in the carpal tunnel space or hypertrophic scar in the skin, neuroma formation in median or palmar cutaneous nerves, tenosynovitis, and hematoma (7, 8). Bleeding and hematoma formation are the expected complications during CTR, and the hematoma by occupying carpal tunnel space and compression on the median nerve may jeopardize the surgery results (9). Using drains is one of the methods to decrease hematoma but its usage is not evaluated in CTR result. Therefore, this study was designed to evaluate the effect of the drain application at the site of surgery to decrease the hematoma formation and hence, improve the results and patients' satisfaction with CTR.

Methods

In this clinical trial study, 62 patients who were candidates for surgical therapy were enrolled. We calculated the sample size according to related articles considering hematoma after CTR (5). We added ten percent to the calculated sample size as drop outs. All patients signed an informed consent. The study was approved by the Ethical Committee of Shahid Sadoughi University of Medical Sciences, Yazd, Iran (IR.SSU.MEDICINE.REC.1397.090) and its protocol was published in the Iranian Registry of Clinical Trials (IRCT20161225031559N3). Exclusion criteria included patients with coagulation disorders or patients who used anticoagulant drugs, those who had a history of previous wrist fractures or surgery, and patients that needed concurrent surgery on the affected hand.

The included patients were divided into intervention and control groups with a random number table. Since after the application of the Penrose drain, some parts of the drain and its skin trajectory were visible to the patient and physician, blinding was impossible to them but we blinded the examiner physician who visited the patients on month three.

All patients in both groups were evaluated for pain with the visual analog scale (VAS) (from 0 for no pain to 10 for maximum pain) and tip pinch strength with the pinch meter (a hydraulic pinch gauge) (10, 11). Patient assessment results were recorded in a checklist, along with demographic information of patients such as age, gender, and involved limb (right or left) and history of underlying metabolic diseases such as diabetes or thyroid disease.

Then, all patients in the intervention and control groups underwent an open CTR surgery with the mini-palm method with surgical loupes under general



anesthesia by one hand surgeon. If the patient was in the intervention group, at the end of the operation, a Penrose drain was inserted in the wound, was passed through a stab incision, just proximal to the distal flexion wrist crease, and then the surgical wound was sutured with nylon and bulky dressing was done. No drain was used in the control group and after wound closure, a bulky dressing was done. In neither of the two groups, tourniquet release and hematosis were performed before wound closure. Two days after surgery, patients were examined, and the Penrose drain was removed in the intervention group. For all patients, the nerve gliding exercise protocol and active finger movements were started. The sutures of all patients were removed two weeks later, and patients were re-evaluated three months after surgery with VAS and pinch power by a blinded surgeon.

Then, the collected data before and three months after surgery were analyzed by SPSS software (version 23, IBM Corporation, Armonk, NY, USA). Moreover, the normality of data was evaluated by the Shapiro-Wilk test, and the results showed that the data did not follow a normal distribution. Therefore, the Mann-Whitney test was used to compare pain and pinch power between the intervention and control groups, and the Wilcoxon signed-rank test was used to compare these data before and after the intervention. A P-value of less than 0.05 was considered significant.

Results

Sixty-two patients were included. Based on the exclusion criteria, six patients were excluded (one for warfarin use, four patients for concurrent hand surgery, and one due to previous wrist bone fractures) (Figure 1). During the study period, ten patients did not participate in the follow-ups; as a result, 46 patients completed the study. The first group or the intervention group (with Penrose drain) consisted of 21 patients, and the second group or the control group (without Penrose drain)

consisted of 25 patients. The two groups had no significant differences in terms of age, gender, and side of involvement (Table 1).

Table 1. Comparison of two groups preoperatively

	With drain (n=21)	Without drain (n=25)	P-value
Age (year) (mean)	52.4	48.5	0.228
Gender (men-women) (%)	7-14	12-13	0.507
Side of involvement (right-left) (%)	47.6-52.4	40.0-60.0	0.604
Preoperative pain (VAS) (mean)	7.762	7.200	0.169
Preoperative pinch power (mean)	5.429	5.436	0.682

VAS: Visual analog scale

Preoperative VAS and pinch power were not different in the two groups (P = 0.169 and P = 0.682, respectively) (Table 1).

Both groups had significant decreases in pain but postoperative pain was not different in the two groups (P = 0.511). Postoperative pinch power in the group with drains was significantly more than in the group without drains (P = 0.026) (Table 2).

Table 2. Comparison of two groups postoperatively

	With drain	Without drain	P-value
Postoperative pain (VAS)	3.238	3.700	0.511
Postoperative pinch power	6.000	4.660	0.025
VAS changes	4.523	3.500	0.206
Pinch changes	0.571	-0.776	< 0.001

VAS: Visual analog scale

The mean VAS score of patients with a drain was 7.762 ± 1.330 preoperatively and it was 3.238 ± 1.510 three months after surgery (P = 0.001), and also the mean pinch power was 5.429 ± 1.540 preoperatively, and 6.000 ± 1.710 postoperatively (P = 0.003). On the other hand, the mean VAS score in the control group was 7.200 ± 1.310 preoperatively and 3.700 ± 1.900 postoperatively (P = 0.001). The mean pinch strength in these patients was 5.436 ± 1.670 preoperatively, and it was 4.660 ± 1.590 postoperatively (P = 0.001). Patients with drain had an increase in pinch power but patients without drain had a decrease in pinch power three months after surgery (Table 2).

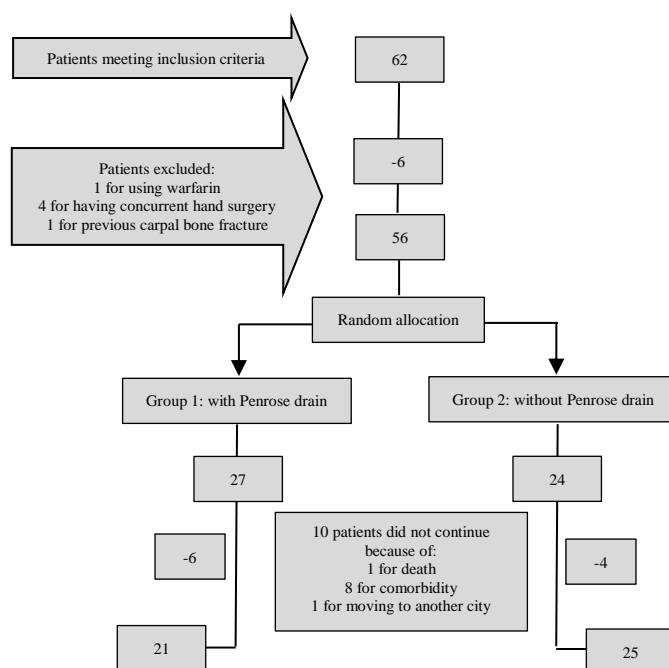


Figure 1. Cases included in this study

The amount of VAS changes in the group with drain was 4.523 and in the group without drain was 3.5 which the difference was not significant ($P=0.206$) (Table 2). In our research, no complications were seen in the patients with Penrose drain after three months of follow-up.

Discussion

Treatment failure and complications occur in 1% to 25% of CTR surgeries. Postoperative hematomas, infections, skin necrosis, as well as intra-operative iatrogenic nerve injuries, are among the factors contributing to the failure of surgical treatment and complications in these patients (11). Among above mentioned deteriorating factors, the postoperative hematoma is less investigated.

Numerous studies have shown the effect of acute hematoma caused by anticoagulant drugs on the median nerve compression and causing acute CTS (11-14). It is assumed that postoperative hematoma can increase postoperative pain and decrease hand function (5). To decrease the risk of hematoma, it is suggested to use a bulky dressing or release the tourniquet and do hemostasis before wound closure or use a drain (15). As far as we know, there is no comprehensive study to evaluate the effect of these three ways on hematoma prevention in CTR surgery.

Hutchinson and Wang compared the results of open CTR in two hands of 18 patients who underwent simultaneous bilateral CTR (5). On one hand, the tourniquet was released and hemostasis was obtained before wound closure, and on the other hand, the wound was closed and dressed before the tourniquet release. They showed that there was no significant difference between the two groups in pain and ecchymosis, and they concluded it was not necessary to add surgical time for tourniquet release and hemostasis in CTR.

In another study, it was mentioned that according to the authors' experience, a bulky dressing was sufficient enough and there was no need to do hemostasis (15).

It seems that hemostasis and electrocautery cannot control bleeding after wound closure completely (5). Therefore, maybe using a drain is more effective for hematoma prevention. There is no similar study in the literature to evaluate the effect of using a drain on CTR surgery results and this study is the first.

According to the results that were obtained three months after the operation, there was more but not a significant improvement in pain as well as a more significant improvement in pinch strength in the intervention group compared to the control group. Although in the control group, in which no drain was used, pain relief was evident after three months postoperatively, pinch strength was decreased compared to preoperative measures. There are few related studies up to this date; thus, little information is available in this field. However, a study by Orak et al. compared the carpal tunnel surgery results in both open and endoscopic surgery (16). It was shown that the pain reduction was better in endoscopic surgery which probably was due to reduced bleeding and less probable hematoma formation in endoscopic surgery, which is in some way consistent with the results of our study.

Infection and tissue reactions are the potential complications of drains application, especially when they are used for extended periods (17). None of our patients had complications related to the Penrose drain.

Although making the examiner blind is the strength of

this study, we could not blind the patients since having or not having the drain was visible to them. The second limitation was following the patient for a short period of three months.

Conclusion

Using a Penrose drain after CTR causes a more outstanding decrease in patients' pain and also increases pinch power compared to patients without a Penrose drain.

Conflict of Interest

The authors declare no conflict of interest in this study.

Acknowledgements

We would like to thank Hamidreza Mirzabagherey for his kind help

References

- Atroshi I, Englund M, Turkiewicz A, Tagil M, Petersson IF. Incidence of physician-diagnosed carpal tunnel syndrome in the general population. *Arch Intern Med.* 2011;171(10):943-4. doi: [10.1001/archinternmed.2011.203](https://doi.org/10.1001/archinternmed.2011.203). [PubMed: 21606100].
- Gelfman R, Melton LJ^{3rd}, Yawn BP, Wollan PC, Amadio PC, Stevens JC. Long-term trends in carpal tunnel syndrome. *Neurology.* 2009;72(1):33-41. doi: [10.1212/01.wnl.0000338533.88960.b9](https://doi.org/10.1212/01.wnl.0000338533.88960.b9). [PubMed: 19122028]. [PubMed Central: PMC2633642].
- Pourmemari MH, Heliovaara M, Viikari-Juntura E, Shiri R. Carpal tunnel release: Lifetime prevalence, annual incidence, and risk factors. *Muscle Nerve.* 2018;58(4):497-502. doi: [10.1002/mus.26145](https://doi.org/10.1002/mus.26145). [PubMed: 29665085].
- Piazzini DB, Aprile I, Ferrara PE, Bertolini C, Tonali P, Maggi L, et al. A systematic review of conservative treatment of carpal tunnel syndrome. *Clin Rehabil.* 2007;21(4):299-314. doi: [10.1177/0269215507077294](https://doi.org/10.1177/0269215507077294). [PubMed: 17613571].
- Hutchinson DT, Wang AA. Releasing the tourniquet in carpal tunnel surgery. *Hand (N Y).* 2010;5(1):57-9. doi: [10.1007/s11552-009-9202-y](https://doi.org/10.1007/s11552-009-9202-y). [PubMed: 19472015]. [PubMed Central: PMC2820624].
- Azar FM, Canale ST, Beaty JH. Campbell's operative orthopaedics. Philadelphia, PA: Elsevier; 2020.
- Schnetzler KA. Acute carpal tunnel syndrome. *J Am Acad Orthop Surg.* 2008;16(5):276-82. doi: [10.5435/00124635-200805000-00006](https://doi.org/10.5435/00124635-200805000-00006). [PubMed: 18460688].
- Duncan KH, Lewis RC, Jr., Foreman KA, Nordyke MD. Treatment of carpal tunnel syndrome by members of the American Society for Surgery of the Hand: Results of a questionnaire. *J Hand Surg Am.* 1987;12(3):384-91. doi: [10.1016/s0363-5023\(87\)80011-4](https://doi.org/10.1016/s0363-5023(87)80011-4). [PubMed: 3584886].
- Neuhaus V, Christoforou D, Cheriyan T, Mudgal CS. Evaluation and treatment of failed carpal tunnel release. *Orthop Clin North Am.* 2012;43(4):439-47. doi: [10.1016/j.ocl.2012.07.013](https://doi.org/10.1016/j.ocl.2012.07.013). [PubMed: 23026459].
- Langley GB, Sheppard H. The visual analogue scale: Its use in pain measurement. *Rheumatol Int.* 1985;5(4):145-8. doi: [10.1007/BF00541514](https://doi.org/10.1007/BF00541514). [PubMed: 4048757].
- Li K, Evans PJ, Seitz WH, Jr., Li ZM. Carpal tunnel syndrome impairs sustained precision pinch performance. *Clin Neurophysiol.* 2015;126(1):194-201. doi: [10.1016/j.clinph.2014.05.004](https://doi.org/10.1016/j.clinph.2014.05.004). [PubMed: 24877682]. [PubMed Central: PMC4234695].
- Sibley PA, Mandel RJ. Atraumatic acute carpal tunnel syndrome in a patient taking dabigatran. *Orthopedics.* 2012;35(8):e1286-e1289. doi: [10.3928/01477447-20120725-37](https://doi.org/10.3928/01477447-20120725-37). [PubMed: 22868623].
- Chadha P, Wordsworth M, Eckersley R. Spontaneous hematoma into the carpal tunnel and palmar aponeurosis. *Eplasty.* 2015;15:ic8. [PubMed: 25671059]. [PubMed Central: PMC4313669].
- Komura S, Hirakawa A, Masuda T, Ito Y, Akiyama H. Recurrent atraumatic acute carpal tunnel syndrome due to hematoma caused by distal radioulnar joint arthritis during

- anticoagulant treatment with apixaban. *Arch Orthop Trauma Surg.* 2017;137(8):1161-4. doi: [10.1007/s00402-017-2730-y](https://doi.org/10.1007/s00402-017-2730-y). [PubMed: [28608274](https://pubmed.ncbi.nlm.nih.gov/28608274/)].
15. Tuncali D, Barutcu AY, Aslan G. Is surgical hemostasis really necessary in open carpal tunnel release? *Plast Reconstr Surg.* 2005;115(7):2160-1. doi: [10.1097/01.prs.0000165484.12750.d1](https://doi.org/10.1097/01.prs.0000165484.12750.d1). [PubMed: [15923892](https://pubmed.ncbi.nlm.nih.gov/15923892/)].
16. Orak MM, Gumustas SA, Onay T, Uludag S, Bulut G, Boru UT. Comparison of postoperative pain after open and endoscopic carpal tunnel release: A randomized controlled study. *Indian J Orthop.* 2016;50(1):65-9. doi: [10.4103/0019-5413.173509](https://doi.org/10.4103/0019-5413.173509). [PubMed: [26955179](https://pubmed.ncbi.nlm.nih.gov/26955179/)]. [PubMed Central: [PMC4759877](https://pubmed.ncbi.nlm.nih.gov/PMC4759877/)].
17. Shibuya Y, Matsumoto G, Sasaki M, Sasaki K, Adachi K, Sekido M. A simple, novel technique for fixing Penrose drains in minor surgeries, with advantages for remote outpatient clinics: A retrospective comparison with conventional drain fixation in North Ibaraki, Japan. *Rural Remote Health.* 2017;17(4):4159. doi: [10.22605/RRH4159](https://doi.org/10.22605/RRH4159). [PubMed: [28978204](https://pubmed.ncbi.nlm.nih.gov/28978204/)].