

# The Clinical Outcome of Transforaminal Lumbar Interbody Fusion and Laminectomy for Single-Level Lumbar Canal Stenosis with Grade 1 and 2 Spondylolisthesis

Ashok Sharma<sup>1\*</sup>, Tarachand Suthar<sup>2</sup>, Mudit Mathur<sup>3</sup>, Vishnu Mittal<sup>4</sup>, Shiv Bhagwan Sharma<sup>5</sup>, Gaurav Mehta<sup>6</sup>

<sup>1</sup> Assistant Professor, Department of Orthopedics, Ananta Institute of Medical Sciences and Research Center, Siyol, Rajsamand, Rajasthan, India

<sup>2</sup> Senior Resident, Department of Orthopedics, Dr. Sampurnanand Medical College, Jodhpur, Rajasthan, India

<sup>3</sup> Senior Resident, Department of Orthopedics, Sawai Mansingh Medical College, Jaipur, Rajasthan, India

<sup>4</sup> Resident, Department of Orthopedics, Jhalawar Medical College, Jhalawar, Rajasthan, India

<sup>5</sup> Senior Professor, Department of Orthopedics, Principal and Controller, Jhalawar Medical College, Jhalawar, Rajasthan, India

<sup>6</sup> Assistant Professor, Department of Orthopedics, Govt. Medical College, Kota, Rajasthan, India

\*Corresponding author: Ashok Sharma; Department of Orthopedics, Ananta Institute of Medical Sciences and Research Center, Siyol, Rajsamand, Rajasthan, India. Tel: +91-9983571166  
Email: ashokkra.sharma@gmail.com

Received: 17 March 2023; Revised: 23 May 2023; Accepted: 11 July 2023

## Abstract

**Background:** Lower back pain is a common cause of disability that affects mobility and quality of life (QOL) in both adult and elderly patients. Initial management of lower back pain includes anti-inflammatory drugs, analgesics, physiotherapy, and epidural steroid infiltration. Despite multiple attempts of conservative management, if a patient develops refractory radicular pain with or without neurologic deficit and claudication, surgery is indicated. The two main approaches to surgical intervention include decompression (laminectomy only) and decompression with fusion [transforaminal lumbar interbody fusion (TLIF)].

**Methods:** The study was done between May 2019 and November 2022. In this randomized study, we compared the clinical outcome of TLIF and laminectomy for single-level lumbar canal stenosis with grade 1 and 2 spondylolisthesis. Forty patients with single-level lumbar canal stenosis with grade 1 and 2 spondylolisthesis were randomly divided into two equal groups. Patients in both groups were followed up for 2 years.

**Results:** In this study, we also noted estimated amount of blood loss, procedure time, time taken for ambulation, length of hospitalization, and demography. The Oswestry Disability Index (ODI) scores improved significantly postoperatively. The modified MacNab criteria suggest the outcomes rated as excellent/good rate of 90% in TLIF and 85% in laminectomy.

**Conclusion:** We evaluated that TLIF procedures were associated with slightly more significant improvement in clinical outcomes in all of the scoring systems that were applied; TLIF provides early ambulation but a higher cost of treatment and longer hospital stay compared to laminectomy. Laminectomy procedures are associated with lesser economic burden, hospital stay, and blood loss, as well as shorter surgical duration compared to TLIF.

**Keywords:** Treatment Outcome; Spondylolisthesis; Laminectomy; Spinal Stenosis; Surgical Decompression

**Citation:** Sharma A, Suthar T, Mathur M, Mittal V, Sharma SB, Mehta G. **The Clinical Outcome of Transforaminal Lumbar Interbody Fusion and Laminectomy for Single-Level Lumbar Canal Stenosis with Grade 1 and 2 Spondylolisthesis.** *J Orthop Spine Trauma* 2023; 9(4): 175-9.

## Background

Lower back pain is a common cause of disability that affects mobility and quality of life (QOL) in both adult and elderly patients. There are various factors for the onset of back pain including degenerative disc diseases, facet joint arthropathy, prolapse of the intervertebral disc, spondylolysis, spondylolisthesis, tumors, and infections such as tuberculosis. Initial management of lower back pain includes anti-inflammatory drugs, analgesics, physiotherapy, and epidural steroid infiltration (1). Despite multiple attempts of conservative management, if a patient develops refractory radicular pain with or without neurologic deficit and claudication, surgery is indicated (1, 2). The two main approaches to surgical intervention include decompression (laminectomy only) and decompression with fusion [transforaminal lumbar interbody fusion (TLIF)]. Lumbar spinal fusion was introduced about 70 years ago. It has evolved as a treatment option for symptomatic lumbar degenerative disease (3). TLIF is usually performed if preoperative lumbar spinal deformity and high-grade instability exist that could worsen after laminectomy alone (4).

Interbody fusion can be done by various methods, including posterior lumbar interbody fusion (PLIF), TLIF, minimally invasive TLIF (MI-TLIF), oblique lateral interbody fusion (OLIF), lateral lumbar interbody fusion (LLIF), and anterior lumbar interbody fusion (ALIF). Nowadays, TLIF and MI-TLIF are very effective and commonly performed procedures for the management of lumbar degenerative diseases. Harms and Joeszsky developed a posterior approach for the fusion of the anterior and posterior sections of the spine (5). In 1982, Harms and Rolinger placed bone grafts packed in titanium mesh via a transforaminal route into the disc space, known as TLIF (6).

The lumbar disc degenerates because of an imbalance in its anabolic and catabolic activity (7, 8). The fluid content of the disc reduces along with disease progression or along with increases in age resulting in the formation of fissures in the nucleus pulposus. When dehydration state extends up to annulus fibrosus, the condition is known as chondrosis intervertebralis. In advanced stages of disease progression, there is degenerative destruction of the disc, vertebral endplates, and vertebral bodies (9).

Absolute indications of TLIF include:



Copyright © 2023 Tehran University of Medical Sciences. Published by Tehran University of Medical Sciences.

This work is licensed under a Creative Commons Attribution-NonCommercial 4.0 International license (<https://creativecommons.org/licenses/by-nc/4.0/>). Noncommercial uses of the work are permitted, provided the original work is properly cited.

- Symptomatic moderate-to-high-grade spondylolisthesis, degenerative scoliosis (curve progression  $> 30^\circ$ ), and stenosis associated with instability at the spine
- Facet joint disease and in cases where  $> 50\%$  of the facet joints are resected
- Post-laminectomy instability or revision decompression at the same level
- Failed lumbar fusion with other techniques

Relative indications of TLIF include:

- Lumbar canal stenosis with symptomatic grade 1 and 2 spondylolisthesis not responding to conservative management for more than 3 consecutive months
- Recurrent or massive disc herniation not responding to conservative management for more than 3 consecutive months
- Pseudarthrosis

The goal of this study is to find out the efficacy of TLIF in comparison to laminectomy for single-level lumbar canal stenosis with grade 1 and 2 spondylolisthesis.

## Methods

The Local Ethics Committee has agreed to this study performed under the Department of Orthopedics at SRG Hospital Jhalawar (Rajasthan, India) between May 2019 and November 2022. In our randomized study, we compared the clinical outcome of TLIF and laminectomy for single-level lumbar canal stenosis with grade 1 and 2 spondylolisthesis. Forty patients with single-level lumbar canal stenosis with grade 1 and 2 spondylolisthesis were randomly divided into two equal groups. Patients in both groups were followed up for 2 years. The mean age of the study population was 56 years. Out of 40 patients, 13 patients were between 40 and 49 years, 19 patients were between 50 and 59 years, and 8 patients were between 60 and 69 years.

### Inclusion Criteria of Surgery

- Patient presenting with typical symptoms, like radicular pain, numbness, motor/sensory deficit, and neurogenic claudication
  - Computed tomography (CT) and magnetic resonance imaging (MRI) indicating single-level lumbar canal stenosis with grade 1 and 2 spondylolisthesis
  - History of failed conservative treatment for more than 3 consecutive months or progressive neurological symptoms despite medical management
  - Elderly or adult patients who had the mental ability to give informed consent for treatment and agree to surgery
- Patients having active infection, malignancies, high-grade spondylolisthesis, and other medical co-morbidities were excluded from this study.

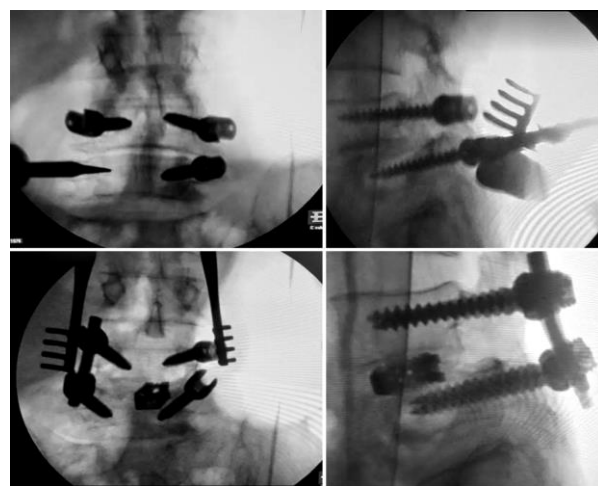
### Preoperative Planning

After obtaining written and informed consent, all patients were thoroughly assessed including history taking and physical and neurological examination. Routine blood investigation, radiographs, MRI, and reverse transcription-polymerase chain reaction (RT-PCR) coronavirus disease 2019 (COVID-19) testing were done. Anterior-posterior and lateral radiographs, CT, and MRI were obtained.

### Surgical Technique of TLIF

The patient was anesthetized under general anesthesia; after that, the patient was laid in prone position over bolster support and the basal values were recorded. The vertebral levels were determined with the help of fluoroscopy. A standard midline incision was made and paravertebral muscles were retracted laterally. The deep dissection was done to expose transverse processes

and facet joints on both sides. With the help of fluoroscopy, an entry point was identified for pedicle screw insertion. Poly-axial pedicle screws were inserted in the pedicle with great care (Figure 1). Then, decompression of the canal was performed by laminectomy. We performed laminectomy unilaterally or bilaterally as required according to the side of radicular pain, neurological deficit, preoperative evaluation, and imaging. Unilateral decompression was performed if complaint was unilateral only, and bilateral laminectomy was performed if complaint existed in both lower extremities. The bleeding was controlled with the help of bipolar cautery. Connecting rod was placed in between pedicle screws, and distraction was done (opposite side to planned facetectomy). After that, we performed facetectomy from the pathological side by using an osteotome and a mallet. Proper care was taken to prevent injury or weakening of the pedicles, especially in patients with osteoporosis. Then, Inferior articular process of one facet joint, and ligamentum flavum was excised to expose the exiting and traversing nerve roots.



**Figure 1.** Intraoperative fluoroscopy images, showing pedicle screw insertion and interbody fusion by using metallic cage and bone graft

We entered up to the disc level between the nerve root and the dura, and the disc material was carefully excised by sequential shavers/reamers. Upper and lower endplates were excised with rasps; care must be taken to avoid injury to anterior structures and anterior longitudinal ligaments. The disc material and the endplate residues were completely removed and the intervertebral disc space was washed with saline. At this time, we checked for the integrity of anterior longitudinal ligament (ALL) anteriorly. A special inserter can be used for graft placement in the disc space; later, a cage loaded with bone graft was placed appropriately in distracted interbody space. Then, we released the distraction at pedicle screws; another rod was also placed, and compression was achieved at anterior elements. After proper fixation, wound closure suction drain was placed for 24 hours under the skin and the wound was closed in usual manner.

### Postoperative Care

The patient was mobilized on postoperative day 1 with the help of a walker. Wound closure suction drain was kept for 24 hours. The first follow-up was done in the outpatient clinic after a 15-day interval, and stitches were removed at the first follow-up in all patients. For the first 6 weeks,

supportive walking started. Physiotherapy was recommended until 3 months. The patient begins full activity and returns to work after 6 months.

**Complications**

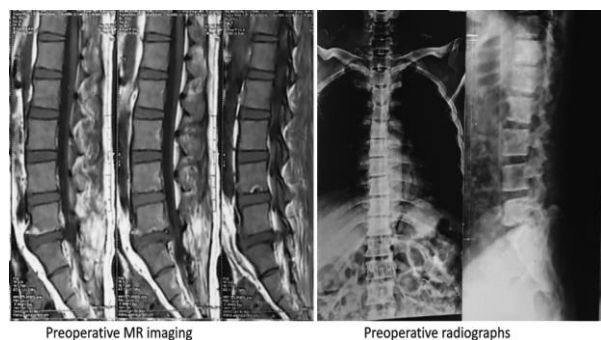A patient with successful TLIF or laminectomy operation has no further complaints (10, 11). Possible complications include vascular injury, anterior longitudinal ligament rupture, neurological injury, pulmonary embolism, deep vein thrombosis (DVT), dural tear, cauda equina injury, postoperative transient radiculopathy of L5 nerve root (12), infection, displacement of instrumentation, pseudoarthrosis, and failed back surgery syndrome (FBSS). Nerve root irritation is typically caused by inappropriately low and medial positioning of the screws following transpedicular screw placement in 1% of cases (13).

**Results**

We compared the estimated amount of blood loss, procedure time, time taken for ambulation, and length of hospitalization in both of the groups. Follow-up examinations were conducted and the outcome was recorded at 3, 12, and 24 months postoperatively. Postoperative radiographs were taken at different follow-ups, and MRI or CT imaging was performed only if needed.

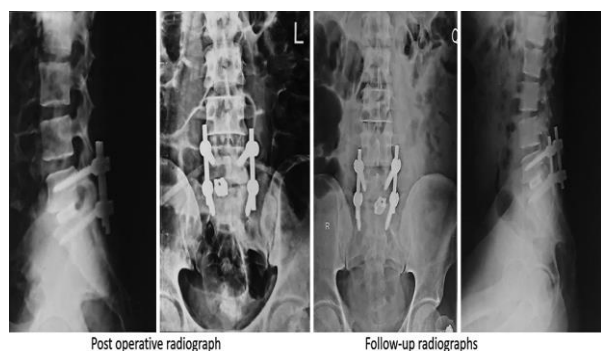
**Radiological Evaluation**

Patients were operated (TLIF and laminectomy) for single-level lumbar canal stenosis with grade 1 and 2 spondylolisthesis, and then, radiographs were taken at different follow-ups, suggesting interbody fusion with cage (Figures 2-4).

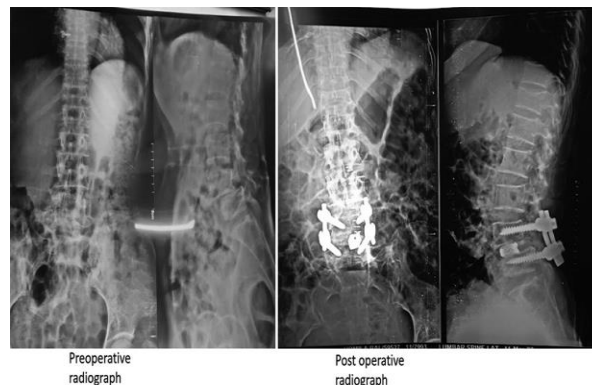


**Figure 2.** Preoperative radiographs and magnetic resonance imaging (MRI) of case 1, showing lumbar degenerative disease (canal stenosis)

Implant-related complications such as implant dislodgement, implant breakage, and pseudoarthrosis were not recorded in any case.



**Figure 3.** Postoperative and follow-up radiographs of case 1, showing transforaminal lumbar interbody fusion (TLIF) at L5-S1, follow-up radiograph showing union, no implant dislodgement, or breakage

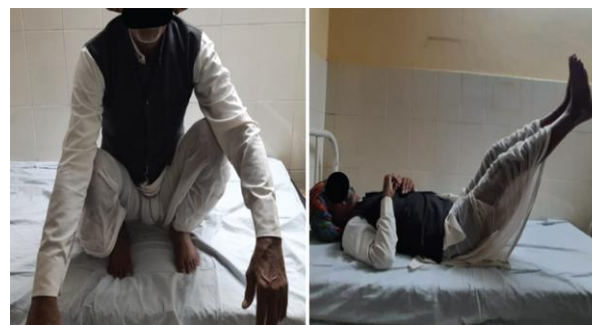

**Figure 4.** Preoperative and postoperative radiographs of case 2, showing transforaminal interbody fusion

**Clinical Evaluation**

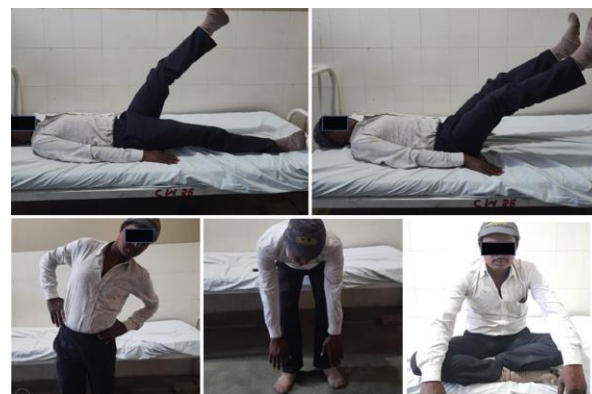For TLIF surgery, the average operation time was 137 minutes, the average estimated blood loss was ~170 ml, the time taken for ambulation was 1<sup>st</sup> postoperative day, and the average length of hospitalization was 6 days. For laminectomy procedure, the average operation time was 85 minutes, the average estimated blood loss was 90 ml, the time taken for ambulation was the 4<sup>th</sup> postoperative day, and the average length of hospitalization was 5 days.

The Oswestry Disability Index (ODI) score was recorded 55.1 ± 2.6%, 26.6 ± 2.2%, 20.1 ± 2.1%, and 17.6 ± 0.1% preoperatively, 3 months, 12 months, and 24 months postoperatively, respectively, for TLIF (Figure 5).



**Figure 5.** Clinical outcome after transforaminal lumbar interbody fusion (TLIF) surgery

The ODI score was recorded 54.9 ± 2.9%, 27.5 ± 2.5%, 23.5 ± 1.5%, and 21.2 ± 1.2% preoperatively, 3 months, 12 months, and 24 months postoperatively, respectively, for laminectomy (Figure 6, Table 1).



**Figure 6.** Clinical outcome after laminectomy, mobility of spine is mostly preserved

**Table 1.** Comparison of complications in different studies of lateral closed wedge osteotomy

ODI	TLIF (mean ± SD)	Laminectomy (mean ± SD)	P-value
Pre operation	55.1 ± 2.6	54.9 ± 2.9	0.89
3 months post operation	26.6 ± 2.2	27.5 ± 2.5	0.70
12 months post operation	20.1 ± 2.1	23.5 ± 1.5	0.92
24 months post operation	17.6 ± 0.1	21.2 ± 1.2	0.76

Showing comparison of the mean scores of two groups

ODI: Oswestry Disability Index; TLIF: Transforaminal lumbar interbody fusion; SD: Standard deviation

The modified MacNab criteria in TLIF showed excellent outcomes in 70% of patients, good in 20%, fair in 10%, and no poor outcome at final follow-up.

The modified MacNab criteria in laminectomy showed excellent outcomes in 40% of patients, good in 45%, fair in 10%, and 5% poor outcomes at final follow-up (Table 2). In this study, one patient with laminectomy was complicated with dural tear, which was intraoperatively managed with dural tear repair.

**Table 2.** Modified MacNab criteria at final follow-up

Modified MacNab criteria at final follow-up	TLIF	Laminectomy
Excellent [n (%)]	14 (70)	8 (40)
Good [n (%)]	4 (20)	9 (45)
Fair [n (%)]	2 (10)	2 (10)
Poor [n (%)]	0 (0)	1 (5)
Excellent/good rate (%)	90	85

TLIF: Transforaminal lumbar interbody fusion

## Discussion

Initially, decompression without fusion was the surgical option of choice; later on, Herkowitz and Kurz provided strong evidence for the success of the decompression with fusion. In this trial, non-instrumented intertransverse process fusion was performed with iliac bone graft (14). Barth et al. showed in their study that the rate of recurrent disc bulge after radical discectomy and limited discectomy was 12.5% and 10%, respectively (15). Because of instability after radical discectomy, high recurrence rates were seen (16).

Since Cloward's (17) original description, numerous modifications of TLIF procedure have been described to improve arthrodesis rates and surgical techniques (18-20). Stability improved in both PLIF and TLIF procedures because the bone graft was placed along the weight-bearing axis. The graft achieves maximal compression with both the anterior and posterior columns because it is placed near the center of rotation which provides greater stability (17).

Ames et al. performed a series of experiments, and they noticed that no significant difference was found in flexibility across grafted levels for any motions when compared to an intact specimen with a single-level TLIF/PLIF (21). Using pedicle screws after single-level interbody graft placement increases rigidity, decreases graft loosening, reduces pseudoarthrosis rate, and enhances the stability of the construct (21). The vascularity of interbody space is more compared to the posterolateral space; therefore, it also enhances the rate of solid fusion (22). This improves the blood supply to the grafts. According to Wolff's law, fusion potential is enhanced if grafts are placed under compression. Finally, interbody fusion helps to restore disc space height, the coronal and sagittal balance of the spine, and lumbar lordosis (22).

Ghogawala et al. performed a study on "decompression surgery with or without instrumented fusion for lumbar canal stenosis in patients with low grade lumbar degenerative spondylolisthesis", and they

found clinically better improvement in health-related QOL for decompression with fusion group compared to decompression alone at 2, 3, and 4 years postoperatively (23). Our results are comparable to this study by Ghogawala et al. (23).

Buttermann et al. reported an improvement in mean ODI from 63% to 33% three years after fusion surgery for spondylolisthesis (24). Like these studies, our mean preoperative ODI was 55.1% for TLIF, while 3 months postoperatively, it was 26.6%. We found a statistically significant improvement in pain scores [visual analog scale (VAS) and ODI] and a significant improvement in the postoperative straight leg raise (SLR) test at 3- and 6-month follow-ups compared to preoperative scores. Improvement was significant when comparisons were made between 3- and 24-month results. However, patients who are treated with TLIF may also require further surgeries such as implant removal or surgery at the adjacent lumbar level.

## Conclusion

TLIF with cage was performed in our study at one lumbosacral level for canal stenosis with Meyerding grade I and II spondylolisthesis. Our experience with the TLIF procedure confirms the findings of previous studies which provided good clinical results, without significant intraoperative and catastrophic complications. TLIF is an effective option to achieve circumferential fusion and excellent decompression of neural elements without severe complications. Bone graft placement along the weight-bearing axis further enhances the stability of the spine. Segmental fixation of disease spine corrects anatomical deformities and possibly enhances fusion rates. The patient gets immediate relief and achieves well ambulatory status postoperatively. Lumbar canal stenosis with instability is usually managed well with TLIF, but lumbar canal stenosis in the absence of instability can be managed with laminectomy alone. The principles of TLIF surgery are the stabilization and fusion of spinal deformity. The risk of damage to important anatomical structures such as nerve roots, dura, and ligamentum flavum can be minimized in TLIF by opening the neural foramen unilaterally. The primary indications for TLIF are the spinal deformity, instability, and degenerative scoliosis. The average age of lumbar canal stenosis presentation is around 56 years (> 50 years). We recommend decompression with fixation, especially in elderly patients, as it provides better stability.

We evaluated that TLIF procedure was associated with slightly more significant improvement in clinical outcomes among all of the scoring systems that were applied. TLIF provides early ambulation but higher cost of treatment and longer hospital stay compared to laminectomy alone. Laminectomy procedures are associated with lesser economic burden, hospital stay, and blood loss, and shorter surgical duration compared to TLIF.

## Conflict of Interest

The authors declare no conflict of interest in this study.

## Acknowledgements

The authors received no financial support for the research, authorship, and/or publication of this manuscript. The authors certify that they have obtained all appropriate patient consent forms. In the form, the

patients have given their consent for their images and other clinical information to be reported in the journal. The patients understand that their names and initials will not be published and due efforts will be made to conceal their identity, but anonymity cannot be guaranteed (ethics code: 04/73).

## References

- Ahmed SI, Javed G, Bareeqa SB, Shah A, Zubair M, Avedia RF, et al. Comparison of decompression alone versus decompression with fusion for stenotic lumbar spine: A systematic review and meta-analysis. *Cureus*. 2018;10(8):e3135. doi: [10.7759/cureus.3135](https://doi.org/10.7759/cureus.3135). [PubMed: [30345192](https://pubmed.ncbi.nlm.nih.gov/30345192/)]. [PubMed Central: [PMC6188214](https://pubmed.ncbi.nlm.nih.gov/PMC6188214/)].
- Kelleher MO, Timlin M, Persaud O, Rampersaud YR. Success and failure of minimally invasive decompression for focal lumbar spinal stenosis in patients with and without deformity. *Spine (Phila Pa 1976)*. 2010;35(19):E981-7. doi: [10.1097/BRS.0b013e3181c46fb4](https://doi.org/10.1097/BRS.0b013e3181c46fb4). [PubMed: [20386501](https://pubmed.ncbi.nlm.nih.gov/20386501/)].
- Resnick DK, Choudhri TF, Dailey AT, Groff MW, Khoo L, Matz PG, et al. Guidelines for the performance of fusion procedures for degenerative disease of the lumbar spine. Part 8: Lumbar fusion for disc herniation and radiculopathy. *J Neurosurg Spine*. 2005;2(6):673-8. doi: [10.3171/spi.2005.2.6.0673](https://doi.org/10.3171/spi.2005.2.6.0673). [PubMed: [16028736](https://pubmed.ncbi.nlm.nih.gov/16028736/)].
- Resnick DK, Choudhri TF, Dailey AT, Groff MW, Khoo L, Matz PG, et al. Guidelines for the performance of fusion procedures for degenerative disease of the lumbar spine. Part 1: Introduction and methodology. *J Neurosurg Spine*. 2005;2(6):637-8. doi: [10.3171/spi.2005.2.6.0637](https://doi.org/10.3171/spi.2005.2.6.0637). [PubMed: [16028729](https://pubmed.ncbi.nlm.nih.gov/16028729/)].
- Harms JG, Jeszenszky D. Die posteriore, lumbale, interkorporelle Fusion in unilateraler transforaminaler Technik. *Oper Orthop Traumatol*. 1998;10(2):90-102. [In German]. doi: [10.1007/s00064-006-0112-7](https://doi.org/10.1007/s00064-006-0112-7). [PubMed: [17332991](https://pubmed.ncbi.nlm.nih.gov/17332991/)].
- Harms J, Rolinger H. A one-stager procedure in operative treatment of spondylolistheses: Dorsal traction-reposition and anterior fusion (author's transl). *Z Orthop Ihre Grenzgeb*. 1982;120(3):343-7. [In German]. doi: [10.1055/s-2008-1051624](https://doi.org/10.1055/s-2008-1051624). [PubMed: [7113376](https://pubmed.ncbi.nlm.nih.gov/7113376/)].
- Saglam N, Dogan S, Ozcan C, Turkmen I. Comparison of four different posterior screw fixation techniques for the treatment of thoracolumbar junction fractures. *World Neurosurg*. 2019;123:e773-e780. doi: [10.1016/j.wneu.2018.12.030](https://doi.org/10.1016/j.wneu.2018.12.030). [PubMed: [30579033](https://pubmed.ncbi.nlm.nih.gov/30579033/)].
- Jakoi AM, Pannu G, D'Oro A, Buser Z, Pham MH, Patel NN, et al. The clinical correlations between diabetes, cigarette smoking and obesity on intervertebral degenerative disc disease of the lumbar spine. *Asian Spine J*. 2017;11(3):337-47. doi: [10.4184/asj.2017.11.3.337](https://doi.org/10.4184/asj.2017.11.3.337). [PubMed: [28670401](https://pubmed.ncbi.nlm.nih.gov/28670401/)]. [PubMed Central: [PMC5481588](https://pubmed.ncbi.nlm.nih.gov/PMC5481588/)].
- Taher F, Essig D, Lebl DR, Hughes AP, Sama AA, Cammisa FP, et al. Lumbar degenerative disc disease: current and future concepts of diagnosis and management. *Adv Orthop*. 2012;2012:970752. doi: [10.1155/2012/970752](https://doi.org/10.1155/2012/970752). [PubMed: [22567411](https://pubmed.ncbi.nlm.nih.gov/22567411/)]. [PubMed Central: [PMC3335178](https://pubmed.ncbi.nlm.nih.gov/PMC3335178/)].
- Cacan MA, Ucar BY. What every spine surgeon should know about transforaminal lumbar interbody fusion surgery for herniated discs. *Int Orthop*. 2019;43(4):883-9. doi: [10.1007/s00264-018-4251-x](https://doi.org/10.1007/s00264-018-4251-x). [PubMed: [30565176](https://pubmed.ncbi.nlm.nih.gov/30565176/)].
- Deutsch H, Musacchio MJ. Minimally invasive transforaminal lumbar interbody fusion with unilateral pedicle screw fixation. *Neurosurg Focus*. 2006;20(3):E10. doi: [10.3171/foc.2006.20.3.11](https://doi.org/10.3171/foc.2006.20.3.11). [PubMed: [16599416](https://pubmed.ncbi.nlm.nih.gov/16599416/)].
- Potter BK, Freedman BA, Verwiebe EG, Hall JM, Polly DW, Kuklo TR. Transforaminal lumbar interbody fusion: Clinical and radiographic results and complications in 100 consecutive patients. *J Spinal Disord Tech*. 2005;18(4):337-46. doi: [10.1097/01.bsd.0000166642.69189.45](https://doi.org/10.1097/01.bsd.0000166642.69189.45). [PubMed: [16021015](https://pubmed.ncbi.nlm.nih.gov/16021015/)].
- Berquist TH. Imaging of the postoperative spine. *Radiol Clin North Am*. 2006;44(3):407-18. doi: [10.1016/j.rcl.2006.01.002](https://doi.org/10.1016/j.rcl.2006.01.002). [PubMed: [16644358](https://pubmed.ncbi.nlm.nih.gov/16644358/)].
- Herkowitz HN, Kurz LT. Degenerative lumbar spondylolisthesis with spinal stenosis. A prospective study comparing decompression with decompression and intertransverse process arthrodesis. *J Bone Joint Surg Am*. 1991;73(6):802-8. [PubMed: [2071615](https://pubmed.ncbi.nlm.nih.gov/2071615/)].
- Barth M, Weiss C, Thome C. Two-year outcome after lumbar microdiscectomy versus microscopic sequestrectomy: Part 1: Evaluation of clinical outcome. *Spine (Phila Pa 1976)*. 2008;33(3):265-72. doi: [10.1097/BRS.0b013e318162018c](https://doi.org/10.1097/BRS.0b013e318162018c). [PubMed: [18303458](https://pubmed.ncbi.nlm.nih.gov/18303458/)].
- Watters WC<sup>3rd</sup>, Bono CM, Gilbert TJ, Kreiner DS, Mazanec DJ, Shaffer WO, et al. An evidence-based clinical guideline for the diagnosis and treatment of degenerative lumbar spondylolisthesis. *Spine J*. 2009;9(7):609-14. doi: [10.3171/j.spinee.2009.03.016](https://doi.org/10.3171/j.spinee.2009.03.016). [PubMed: [19447684](https://pubmed.ncbi.nlm.nih.gov/19447684/)].
- Cloward RB. The treatment of ruptured lumbar intervertebral discs by vertebral body fusion. I. Indications, operative technique, after care. *J Neurosurg*. 1953;10(2):154-68. doi: [10.3171/jns.1953.10.2.0154](https://doi.org/10.3171/jns.1953.10.2.0154). [PubMed: [13035484](https://pubmed.ncbi.nlm.nih.gov/13035484/)].
- Grob D, Scheier HJ, Dvorak J, Siegrist H, Rubeli M, Joller R. Circumferential fusion of the lumbar and lumbosacral spine. *Arch Orthop Trauma Surg*. 1991;111(1):20-5. doi: [10.1007/BF00390187](https://doi.org/10.1007/BF00390187). [PubMed: [1772720](https://pubmed.ncbi.nlm.nih.gov/1772720/)].
- Kim SS, Denis F, Lonstein JE, Winter RB. Factors affecting fusion rate in adult spondylolisthesis. *Spine (Phila Pa 1976)*. 1990;15(9):979-84. doi: [10.1097/00007632-199009000-00026](https://doi.org/10.1097/00007632-199009000-00026). [PubMed: [2259992](https://pubmed.ncbi.nlm.nih.gov/2259992/)].
- Kozak JA, O'Brien JP. Simultaneous combined anterior and posterior fusion. An independent analysis of a treatment for the disabled low-back pain patient. *Spine (Phila Pa 1976)*. 1990;15(4):322-8. doi: [10.1097/00007632-199004000-00014](https://doi.org/10.1097/00007632-199004000-00014). [PubMed: [2141189](https://pubmed.ncbi.nlm.nih.gov/2141189/)].
- Ames CP, Acosta FL, Chi J, Iyengar J, Muir W, Acaroglu E, et al. Biomechanical comparison of posterior lumbar interbody fusion and transforaminal lumbar interbody fusion performed at 1 and 2 levels. *Spine (Phila Pa 1976)*. 2005;30(19):E562-E566. doi: [10.1097/01.brs.0000180505.80347.b1](https://doi.org/10.1097/01.brs.0000180505.80347.b1). [PubMed: [16205329](https://pubmed.ncbi.nlm.nih.gov/16205329/)].
- Mummaneni PV, Haid RW, Rodts GE. Lumbar interbody fusion: State-of-the-art technical advances. Invited submission from the Joint Section Meeting on Disorders of the Spine and Peripheral Nerves, March 2004. *J Neurosurg Spine*. 2004;1(1):24-30. doi: [10.3171/spi.2004.1.1.0024](https://doi.org/10.3171/spi.2004.1.1.0024). [PubMed: [15291016](https://pubmed.ncbi.nlm.nih.gov/15291016/)].
- Ghogawala Z, Dziura J, Butler WE, Dai F, Terrin N, Magge SN, et al. Laminectomy plus fusion versus laminectomy alone for lumbar spondylolisthesis. *N Engl J Med*. 2016;374(15):1424-34. doi: [10.1056/NEJMoa1508788](https://doi.org/10.1056/NEJMoa1508788). [PubMed: [27074067](https://pubmed.ncbi.nlm.nih.gov/27074067/)].
- Buttermann GR, Garvey TA, Hunt AF, Transfeldt EE, Bradford DS, Boachie-Adjei O, et al. Lumbar fusion results related to diagnosis. *Spine (Phila Pa 1976)*. 1998;23(1):116-27. doi: [10.1097/00007632-199801010-00024](https://doi.org/10.1097/00007632-199801010-00024). [PubMed: [9460161](https://pubmed.ncbi.nlm.nih.gov/9460161/)].