

Clinical and Functional Results Using Autologous Conditioned Serum in the Treatment of Acute Ankle Injuries in Sporting Activities

Koduru Satya Kumar[✉], Balakrishna Bathina, Tankala Jayadev, Manindhar Sane

Department of Orthopaedics, NRI Medical College, Chinakakani, India

✉Corresponding author: Koduru Satya Kumar; Department of Orthopaedics, NRI Medical College, Chinakakani, India. Tel: +91-9000366555, Email: kodurusks@gmail.com

Received: 12 March 2022; Revised: 14 May 2022; Accepted: 17 June 2022

Abstract

Background: Ankle ligament injuries in the sports like basketball, volleyball, and cricket are the most common reasons for missed participation in athletics, accounting for 14% of all sports injuries. These injuries may often require splinting and rest for a longer duration, leading to a permanently reduced level of sports performance. The autologous conditioned cytokine-rich serum (ACRS) is becoming a reliable treatment option in acute ankle injuries as it enhances biological healing. The objective of this study is to evaluate the role of ACRS in acute ankle injuries and report the efficacy of ACRS injections on time to return to physical activities.

Methods: 42 patients with clinical and radiological signs of ankle ligamentous injuries (grades 1 and 2) secondary to sporting or gaming activity were recruited for this study. Each patient received one injection of ACRS at the injury site and was put on a soft cast for one week. Clinical and functional evaluation was performed using the Visual Analogue Scale (VAS), American Orthopaedic Foot and Ankle Society (AOFAS) Ankle-Hindfoot Scale, and the Foot and Ankle Disability Index (FADI) scores before the injection, at one week, i.e., after removing the soft cast, three weeks, six weeks, and three months.

Results: Our study showed gradual improvement of all the evaluation scales at all the follow-ups. Few patients showed minor side effects like aseptic effusion. The least common complaint was a pain in the subsequent days after the injection.

Conclusion: Our results, in conjunction with pre-existing studies in the literature regarding the biological effects of ACRS, demonstrate the viability of this therapy for the treatment of acute ankle injuries, showing the positive influence on pain and healing capacity and returning to gaming activities immediately in about two weeks without significant adverse effects.

Keywords: Ankle Injuries; Cytokines; Interleukin-1 Receptor Antagonist Protein; Athletic Injuries

Citation: Kumar KS, Bathina B, Jayadev T, Sane M. **Clinical and Functional Results Using Autologous Conditioned Serum in the Treatment of Acute Ankle Injuries in Sporting Activities.** *J Orthop Spine Trauma* 2022; 8(3): 87-9.

Background

Injuries around the ankle were common for missed participation in athletics, accounting for 14% of all sports injuries (1). Moreover, ligamentous injuries around the ankle joint are the most common injury among the young population involved in sporting activities like volleyball, basketball, football, cricket, and running on uneven surfaces demonstrating the highest injury prevalence. Ankle sprains account for 80% of all ankle lesions. Sprain involving the lateral ankle ligamentous complex is the most common ankle injury, which involves the anterior talofibular ligament (ATFL) and calcaneofibular ligament (CFL), while more severe injuries involve the posterior talofibular ligament (PTFL). These injuries present with tenderness at the site of injury, swelling over the involved ligaments, and pain on weight-bearing (2).

Ankle sprains are classified clinically based on the severity of the injury and are divided into three grades: grade I, in which the ligaments are minimally stretched, without any mechanical instability of the ankle joint, grade II (moderate), in which the ligaments are partially torn, with moderate pain and swelling around the ankle, and the patient presents with difficulty supporting himself, and grade III, in which the ligaments are completely ruptured, with severe pain, edema and hematoma, and where there is the inability to bear weight with instability (3, 4).

Specialized physical exam techniques and radiographic imaging like ultrasonography (USG) and magnetic resonance imaging (MRI) can aid in diagnosing these injuries. High-resolution USG has advantages over

other imaging modalities as it is portable, easily available, devoid of any radiation exposure, and less expensive (5).

Nearly all ankle sprains can be treated without surgical repair of ligaments. Even a full-thickness ligament tear can heal without surgical repair if proper immobilization protocol is followed. The non-operative treatment strategy, called 'functional treatment', includes the application of the rest, ice, compression, and elevation (RICE) therapy immediately after the injury, a short period of immobilization, protection of the ankle joint using an elastic tape or bandage, and early range of motion (ROM) exercises followed by early weight-bearing and neuromuscular ankle training for most of the grade I and grade II sprains. Severe grade II injuries may require cast boots to provide ankle support. This functional program will take two weeks for minor injuries and 8-12 weeks for more severe injuries to heal (6).

Treatment of grade III sprains requires a short period of immobilization using a short leg cast of 2-3 weeks followed by ankle ROM exercises, muscular training, and proprioceptive training. Poor balance often leads to recurrent sprains and results in chronic ankle instability. A simple balancing exercise is standing on the injured foot with the contralateral foot raised and eyes closed. Balance boards are often used in this stage of rehabilitation (7).

Our study aims to evaluate the efficacy of autologous conditioned cytokine-rich serum (ACRS) in ankle sprains in terms of rapid pain relief and to decrease the time taken to return to activity. The use of orthobiologic substances like stem cells, platelet-rich plasma (PRP), ACRS, etc., has evolved to the extent that it significantly influences current orthopedic



practice. The concept of biological therapies can enhance the healing mechanism of tissues that have limited healing potential due to poor vascular supply like tendons, cartilage, meniscus, and ligaments. The release of pro-inflammatory mediators like interleukin-1 (IL-1) and other destructive factors following injury result in further destruction of musculoskeletal tissues. ACRS is rich in IL-1 receptor antagonist (IL-1Ra), which acts against IL-1 beta (IL-1β) and tumor necrosis factor alpha (TNF-α) and prevents further destruction (8). In addition to anti-inflammatory mediators, ACRS also has several growth factors and cytokines (Table 1), which can augment the synthesis and remodelling of damaged tissue and provide early relief from pain (9, 10).

Cytokine	N	Concentration in ACS
IL-1Ra	224	2015.0
IL-1β	224	7.9
IL-6	200	28.7
TNF-α	92	10.1
IL-10	92	33.4
FGF-2	92	26.6
VEGF	92	508.6
IGF-1	92	117209.0
PDGF-AB	92	39026.0
TGF-β	80	97939.0

Number of samples tested; **Concentration values are averages, given in picograms per milliliter before and after incubation
 ACS: Autologous conditioned serum; IL: Interleukin; IL-1Ra: Interleukin-1 receptor antagonist; IL-1β: Interleukin 1 beta; TNF-α: Tumor necrosis factor alpha; FGF-2: Fibroblast growth factor 2; VEGF: Vascular endothelial growth factor; IGF-1: Insulin-like growth factor 1; PDGF-AB: Platelet-derived growth factor-AB; TGF-β: Transforming growth factor beta

Methods

This observational study was performed on 42 patients (36 men and 6 women) aged 18-30 years at orthopaedic department of NRIGH, orthocare clinic, Vijayawada, India, during September 2019 to September 2021. 35 patients had injury on their right side and 7 on the left side. Follow-up was done at 2 weeks, 6 weeks, and 3 months after treatment. Inclusion criteria included clinical and radiological signs of ankle ligamentous injuries (grades 1 and 2) secondary to sporting or gaming activity, willingness for the study, platelet count (minimum 2 lakhs per dl), erythrocyte sedimentation rate (ESR) and C-reactive protein (CRP) in normal limits, hemoglobin (Hb) > 10 g/dl, and random blood sugar (RBS) < 160 mg/dl on the day of therapy. Exclusion criteria included previous surgeries to the ankle, active urine infection or people with diabetes with uncontrolled blood sugar and active skin lesions in and around the injection site, platelet dysfunction syndrome/critical thrombocytopenia (<10000 /ml), septicemia, coagulopathies, presence of tumors or metastasis, pregnancy or breastfeeding, immunodeficiencies, and vascular injuries.

Preparation and Procedure: 2 CC of ACRS obtained was injected into the injury site under the guidance of USG (Figures 1 and 2).

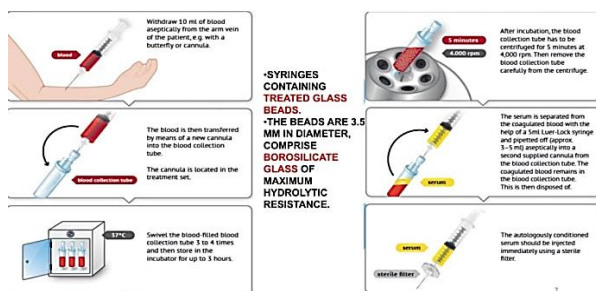


Figure 1. Schematic representation of the preparation

- Post-injection protocol included the following items:
 - No non-steroidal anti-inflammatory drugs (NSAIDs), no steroids
 - Avoiding strenuous physical activities
 - Strengthening exercises, swimming, and cycling are encouraged
 - Paracetamol taken as required (SOS) for pain



Figure 2. Steps of autologous conditioned cytokine-rich serum (ACRS) preparation

Results

Results were assessed by the following criteria:

A. American Orthopaedic Foot and Ankle Society (AOFAS) Ankle-Hindfoot Scale: Time frame is six months. Evaluation is based on pain (40 points), function (50 points), and alignment (10 points). The best score is 100 points, and 0-50 is poor.

B. Visual Analogue Scale (VAS): Time frame is six months. Subjective assessment of pain is based on a scale of 0 to 10, when 0 is no pain and 10 is severe pain.

C. Foot and Ankle Disability Index (FADI) Score: Time frame is six months. It assesses difficulty level in standing, walking on flat and uneven ground, walking on inclines, and the duration of walking without difficulty. It also evaluates sporting activities.

The location of the injury is given in [table 2](#). The results are as follows:

AOFAS scale: 96-100 points in 34 cases

VAS score: 0-2 in 34 cases

FADI score: 130 points in 34 cases

Type of injury	Number
Lateral ligament injuries	28
Medial ligament injuries	8
Both lateral and medial	6
Total	42

Six cases came back with swelling on examination at the end of week one, that was aseptic effusion of the ankle ([Figure 3](#)). The remaining 2 cases were lost to follow up.

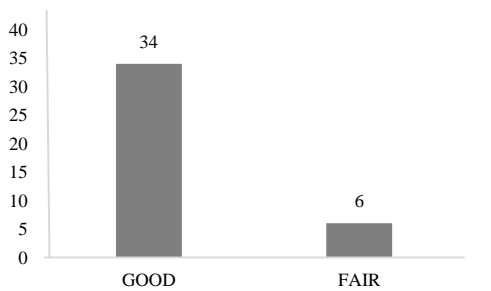


Figure 3. Results

Discussion

Our study has shown that ACRS is effective in ankle sprains in terms of rapid pain relief, returning to early sporting activities, and enhancing the biological healing of ankle sprains. ACRS helps in the biological healing of sprains and restores tissue homeostasis as it is rich in numerous signalling cytokines and growth factors that are important in tissue repair by various mechanisms, including decreasing inflammation in the acute phase, angiogenesis, and synthesis and remodelling of injured tissue although the mechanism is still not understood completely. ACRS being rich in IL-1Ra is found to be cost-effective when compared to synthetic IL-1Ra. ACRS injection in treating musculoskeletal injuries has become more popular in recent years. Recent studies have shown that ACRS injections are relatively safe and can potentially accelerate or augment the tissue healing process (11). The risk of adverse effects is minimal as it is prepared from the

patient's blood. ACRS has been established in showing clinical improvements in patients with osteoarthritis (OA). Further studies are required to determine the effects of ACRS on ankle sporting injuries.

Conclusion

ACRS is a relatively new alternative option that is also safe as it is derived from the patient's own blood. ACRS contains many growth factors that are found to be effective in enhancing the healing of ankle injuries. ACRS can be a promising treatment option, but it requires further studies with clinical evidence to support its use in acute ankle injuries.

Conflict of Interest

The authors declare no conflict of interest in this study.

Acknowledgements

None.

References

- Fong DT, Chan YY, Mok KM, Yung PS, Chan KM. Understanding acute ankle ligamentous sprain injury in sports. *Sports Med Arthrosc Rehabil Ther Technol*. 2009;1:14. doi: [10.1186/1758-2555-1-14](#). [PubMed: [19640309](#)]. [PubMed Central: [PMC2724472](#)].
- Roos KG, Kerr ZY, Mauntel TC, Djoko A, Dompier TP, Wikstrom EA. The epidemiology of lateral ligament complex ankle sprains in National Collegiate Athletic Association Sports. *Am J Sports Med*. 2017;45(1):201-9. doi: [10.1177/0363546516660980](#). [PubMed: [27573356](#)].
- Porter DA. Ligamentous injuries of the foot and ankle. In: Fitzgerald RH, Kaufer H, Malkani AL, editors. *Orthopaedics*. St. Louis, MO: Mosby 2002.
- Delee JC, Drez DJ. *Orthopaedic sports medicine: Principles and practice*. Vol 2. Philadelphia, PA: Saunders; 2003.
- Mei-Dan O, Kots E, Barchilon V, Massarwe S, Nyska M, Mann G. A dynamic ultrasound examination for the diagnosis of ankle syndesmotric injury in professional athletes: A preliminary study. *Am J Sports Med*. 2009;37(5):1009-16. doi: [10.1177/0363546508331202](#). [PubMed: [19336613](#)].
- Lynch SA, Renstrom PA. Treatment of acute lateral ankle ligament rupture in the athlete. Conservative versus surgical treatment. *Sports Med*. 1999;27(1):61-71. doi: [10.2165/00007256-199927010-00005](#). [PubMed: [10028133](#)].
- Gauffin H, Tropp H, Odenrick P. Effect of ankle disk training on postural control in patients with functional instability of the ankle joint. *Int J Sports Med*. 1988;9(2):141-4. doi: [10.1055/s-2007-1024996](#). [PubMed: [3384520](#)].
- Wehling P, Moser C, Frisbie D, McIlwraith CW, Kawcak CE, Krauspe R, et al. Autologous conditioned serum in the treatment of orthopedic diseases: The orthokine therapy. *BioDrugs*. 2007;21(5):323-32. doi: [10.2165/00063030-200721050-00004](#). [PubMed: [17896838](#)].
- Evans CH, Chevalier X, Wehling P. Autologous conditioned serum. *Phys Med Rehabil Clin N Am*. 2016;27(4):893-908. doi: [10.1016/j.pmr.2016.06.003](#). [PubMed: [27788906](#)].
- Woodell-May J, Steckbeck K, King W. Potential mechanism of action of current point-of-care autologous therapy treatments for osteoarthritis of the knee-a narrative review. *Int J Mol Sci*. 2021;22(5). doi: [10.3390/ijms22052726](#). [PubMed: [33800401](#)]. [PubMed Central: [PMC7962845](#)].
- Frizziero A, Giannotti E, Oliva F, Masiero S, Maffulli N. Autologous conditioned serum for the treatment of osteoarthritis and other possible applications in musculoskeletal disorders. *Br Med Bull*. 2013;105:169-84. doi: [10.1093/bmb/lds016](#). [PubMed: [22763153](#)].