

The Dorr Type and Cortical Thickness Index Just Below the Lesser Trochanter and Its Comparison with Cortical Thickness Index Ten Centimeters Below the Tip of the Lesser Trochanter: A Cross-Sectional Study

Alireza Sadeghpour¹, Seyed Hamed Ghaffari^{2,3}, Jafar Ganjpour Sales³, Hossein Aslani³, Ali Hossein Zeinalzadeh⁴

¹ Professor, Department of Orthopedic Surgery, Shohada Educational Hospital, School of Medicine, Tabriz University of Medical Sciences, Tabriz, Iran

² Orthopedic Surgeon, Department of Orthopedic Surgery, Shohada Educational Hospital, School of Medicine, Tabriz University of Medical Sciences, Tabriz, Iran

³ Associate Professor, Department of Orthopedic Surgery, Shohada Educational Hospital, School of Medicine, Tabriz University of Medical Sciences, Tabriz, Iran

⁴ Assistant Professor, Department of Community and Family Medicine Specialist, Social Determinants of Health Research Center, School of Medicine, Tabriz University of Medical Sciences, Tabriz, Iran

*Corresponding author: Seyed Hamed Ghaffari; Department of Orthopedic Surgery, Shohada Educational Hospital, School of Medicine, Tabriz University of Medical Sciences, Tabriz, Iran. Tel: 9141297196, Email: s.hamedghaffari@yahoo.com

Received: 17 April 2022; Revised: 13 June 2022; Accepted: 01 July 2022

Abstract

Background: Quality of the bone before surgery determines the choice of the appropriate prosthesis and the surgical approach as well as the result of total hip arthroplasty (THA). The proximal femur morphology determines the decision of cemented or uncemented THA, and the Dorr classification is often employed for this purpose.

Methods: 100 patients over the age of 40 who had been referred to the emergency department of Shohada Hospital, Tabriz, Iran, for any reason and had an accurate pelvic anteroposterior (AP) X-ray with proximal femur were included in this study, and Dorr classification and mean cortical thickness index (CTI) just below the lesser trochanter and 10 cm below it were measured.

Results: In this study, the Dorr classification differed significantly in men and women, and type C was higher in women. Classification is strongly subjected to the surgeon's clinical experience, and training class significantly affects it. There was a significant relationship ($P < 0.001$) between the CTI 10 cm below the trochanter and just below it.

Conclusion: The proximal femur morphology covers a wide range. Therefore, it is difficult to determine the exact morphology, especially for groups B and C. There was also a significant correlation between the mean CTI below the lesser trochanter and 10 cm below it. Therefore, we think this is a practical and most straightforward method for classifying proximal femur morphology with cortical index (CI) just below the lesser trochanter and 10 cm below it, especially for inexperienced training residents.

Keywords: Femoral Neck Fractures; Total Hip Arthroplasty; Classification

Citation: Sadeghpour A, Ghaffari SH, Ganjpour Sales J, Aslani H, Zeinalzadeh AH. **The Dorr Type and Cortical Thickness Index Just Below the Lesser Trochanter and Its Comparison with Cortical Thickness Index Ten Centimeters Below the Tip of the Lesser Trochanter: A Cross-Sectional Study.** *J Orthop Spine Trauma* 2022; 8(3): 79-82.

Background

Each year, about 60000 hip fractures occur in the United Kingdom (UK), principally in older women, with mortality rate of 10-20 percent above that is expected based on age and sex (1). Femoral neck fractures are associated with a high rate of mortality, morbidity, and social dependency among the elderly (2-4). Bone quality of the femoral bone represents a significant determinant in therapeutic options and durability of total hip replacement. Several X-ray classifications have been proposed to help assess trabecular or cortical bone quality (5, 6).

Internal fixation, hemiarthroplasty, and total hip arthroplasty (THA) are all possibilities for treating intracapsular femoral neck fractures. Although hemiarthroplasty allows for a shorter surgery time and earlier mobilization, the functional outcomes are inferior, and the inability to support correction later is more notable (7). Hence, it is dedicated to patients who are less capable of tolerating surgery and anesthesia and have a limited life expectancy and exercise tolerance (8-10).

Preoperative evaluation of femoral bone quality is essential when choosing a design and fixation method for femoral components. The Dorr classification is commonly

used to assess the quality of femoral bone (11). In this classification, femoral bone quality is divided into three types using anteroposterior (AP) and lateral plain radiographs of the hip joint. Type A is a sufficiently thick bone cortex in AP and lateral views. Type C is an extremely thin bone cortex with a stovepipe shape in AP view, a widened medullary cavity, and indistinct cortical bone in lateral view. Type B is between types A and C and comprises a thin cortical bone with a residual funnel shape in the AP view and an indistinct bone cortex at the posterior of the femur with a nonuniform line on the medullary cavity side of the bone in the lateral view. The Dorr classification, on the other hand, just categorizes the look of plain radiographs and has no quantitative requirements. There are currently just a few types of research looking into the Dorr classification's intra-examiner and inter-examiner reliability (11, 12).

Methods

This cross-sectional study was performed in one year, from 2019 to 2020, on patients aged 40 years and older who referred to Shohada Hospital, Tabriz, Iran, for any reason. This study included radiographs that were true AP view of pelvic and proximal 10 cm of the femur. At first, the



cortical thickness index (CTI) of all radiographs was measured just below and 10 cm below the lesser trochanter by two orthopedic residents who were blind to the study method. Only radiographs showing a similar cortical index (CI) measurement between the two residents were included in this study. The CI was used for Dorr classification because there are no other quantitative criteria. A total of 100 radiographs were utilized for analysis. We used the cutoff point of 0.58 between types A and B and 0.49 between types B and C, according to the Nakaya et al. study (12).

On AP radiographs, the CTI was defined as the ratio of cortical width minus endosteal width to cortical width at the height of 100 mm below the lesser trochanter's tip. Cortices with higher values were thicker. Type A had thick cortices that began at the distal end of the lesser trochanter and thickened quickly, producing a funnel shape and a narrow diaphyseal canal, according to the Dorr description of proximal femoral morphology. Type B showed proximal bone loss and a widening of the diaphyseal canal. The thickness of the cortices was significantly reduced in type C, resulting in a wide intramedullary canal and a fuzzy look to the bone cortices (11).

At the second step, all radiographs converted to a PowerPoint presentation were shown to three groups consisting of 4 hip surgeons, 15 senior residents, and 15 junior residents. Before each round, participants gave a short Dorr classification presentation. The radiographs were shown in PowerPoint slides randomly; thus, the participants were blind. With new radiograph random order, the same test was performed two weeks later to assess intraobserver reliability and changes in interobserver reliability.

We used Kappa values for distinguishing the valid agreement of every observation and interobserver and intraobserver reliability (poor agreement: Kappa < 0, slight: 0-0.20, fair: 0.21-0.40, moderate: 0.41-0.60, substantial: 0.61-0.80, almost perfect: 0.81-1.00) (13).

Results

Fifty patients were excluded. The remaining 100 individuals' proximal femurs were classified as Dorr type. According to the results, 49 patients (49%) were women, and 51 patients (51%) were men. Seventeen patients (17%) were of type A, 64 patients (64%) were type B, and 19 patients (19%) were type C according to Dorr classification.

According to the results obtained in the first round, the highest agreement among the junior residents, the senior residents, and the hip surgeons was on type A (73.1%) and the lowest agreement was on type C (42.1%). The highest agreement was on type B (81.2%) in the second round and the lowest was on type C (47.3%).

According to the comparison of the two rounds with each other, the agreement on type A in the two rounds was not significantly different from each other (73.1% in the first round and 76.3% in the second round), but type B in the first and second rounds was significantly different (63.7% in the first round and 81.2% in the second round). Moreover, type C had a significant difference in the two rounds (42.1% in the first round and 47.3% in the second round). The agreement rate between residents increased from 59.3% to 68.1%, which was significantly different (Figure 1).

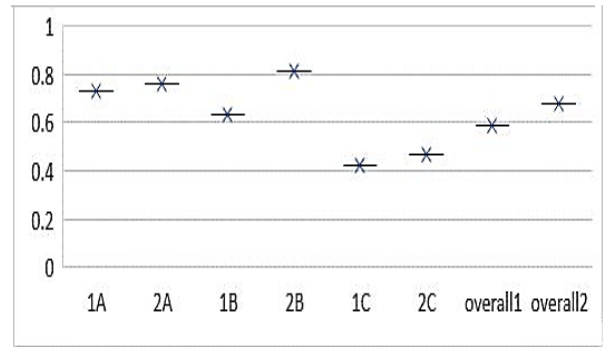


Figure 1. Total agreement comparison

The agreement between junior residents and seniors was also compared, with the highest agreement in type A (67.7%) and the lowest in type C (38.6%) in the first round. The highest agreement was on type B (76.3%) in the second round, and the lowest agreement was on type C (45.6%).

According to the comparison between the two rounds, there was no significant difference in type A between the two rounds (67.7% of the first round to 69.9% in the second round). In the case of type B, there was a significant difference between residents between the two rounds, from 66.1% to 76.3%. In addition, type C had a significant difference between the two rounds, from 38.6% to 45.6%. In general, the agreement reached from 57.4% to 63.7%, which was a significant difference (Figure 2).

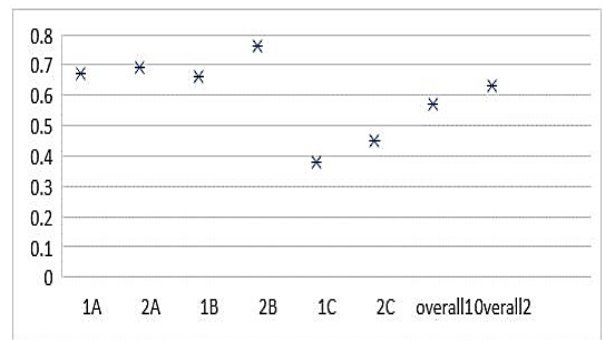


Figure 2. Agreement comparison between two rounds

Dorr type was significantly associated with the CTI just below the trochanter (P < 0.001), and the mean CTI in type C decreased significantly (Table 1).

Table 1. Mean cortical thickness index (CTI) just below the lesser trochanter compared by Dorr type

Dorr type	CTI (mean ± SD)
A	0.600 ± 0.009
B	0.500 ± 0.100
C	0.350 ± 0.050

CTI: Cortical thickness index; SD: Standard deviation

The mean CTI was dramatically higher in men than in women, 10 cm below the small trochanter and just below the small trochanter (Table 2).

Table 2. Mean cortical thickness index (CTI) compared by gender

	Men (mean ± SD)	Women (mean ± SD)	P-value
Mean CTI 10 cm below the lesser trochanter	0.57 ± 0.10	0.49 ± 0.11	0.001
Mean CTI just below the lesser trochanter	0.51 ± 0.10	0.43 ± 0.12	0.001

CTI: Cortical thickness index; SD: Standard deviation

According to the results, 14.3% of the women were of type A in the Dorr classification, 55.1% were type B, and 30.6% were type C. 19.6% of the men were of type A, 72.5% were type B, and 21.1% were type C. Dorr classification was significantly associated with gender. Type C was significantly higher in women than men ($P < 0.001$).

The mean CTI 10 cm below the trochanter was 0.53 ± 0.11 , and the mean CTI just below the trochanter was 0.47 ± 0.12 . According to the results of Pearson analysis, there was a strong correlation ($r = 0.93$) and a significant relationship ($P < 0.001$) between the CTI 10 cm below the trochanter and just below the trochanter (Figure 3).

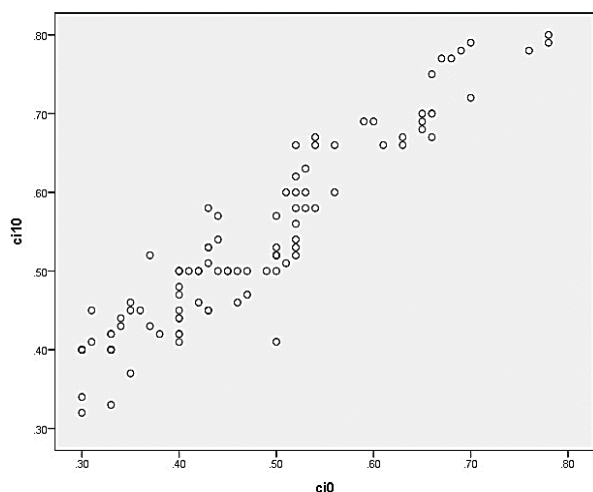


Figure 3. Correlation between cortical thickness index (CTI) just below the trochanter and 10 cm below the trochanter

Discussion

This study used the standard index measurement method to examine the relationship between Dorr type and CTI below the lesser trochanter. To assess the CI based on the results, help determine the type of prosthesis, and ultimately reduce the results of total hip replacement and its consequences, it is better to compare the thickness of the cortex 10 cm below the lesser trochanter.

Dorr proximal femoral types are linked to a higher incidence of intraoperative fracture and more severe osteoporosis (13). Dorr type C femurs are more prevalent in older women with a lower body weight, which is consistent with findings of this study. These femurs are structurally and cellularly compromised, making them unsuitable for implant fixation (11, 13). Worse Dorr proximal femoral types correlated with lower CTIs (13).

Asian women's proximal femurs are smaller (14, 15). Even a narrow-stem Austin-Moore prosthesis may be too tight to install in persons with extremely small proximal femurs, necessitating femur rasping and risking fractures. In intra-operative fractures, the Dorr types may not be as large a risk factor. Another strategy to predict hazards and difficulties and advise fixation method selection is to template the opposing femur before surgery. Predicting patients at risk of intra-operative fracture or postoperative dislocation using the CTI and Dorr proximal femoral types can help guide prosthesis and fixation method selection.

Proximal femoral morphology varies with age, race, sex, and lifestyle (11, 15-19). Some pathological factors such as rheumatoid arthritis (RA), atrophic osteoarthritis (OA), osteoporosis, and some metabolic bone diseases may affect

femoral geometry (20). Type C bone is found mainly in older and underweight women (21), consistent with the findings of study. However, smaller height may also play an important role, as reported. Asian populations, such as Koreans, measure more canal flare index (CFI) regardless of gender (16). In other studies, type C is less common in older women with lower body weight (22).

Conclusion

The proximal femur morphology covers a wide range. Therefore, it is difficult to determine the exact morphology, especially for groups B and C. classification is strongly subjected to the surgeon's level of clinical experience and radiographic interpretation. In our study, the training class had a significant effect. Dorr classification was significantly associated with the mean CTI below the trochanter. There was also a significant correlation between the mean CTI just below the trochanter and 10 cm below the trochanter; thus, we believe that using CI just below the lesser trochanter rather than 10 cm below the lesser trochanter is a practical and straightforward method for classifying proximal femur morphology, especially for inexperienced training residents.

Conflict of Interest

The authors declare no conflict of interest in this study.

Acknowledgements

The authors would like to thank the Shohada Clinical Research Development Unit, Shohada Hospital, Tabriz University of Medical Sciences.

The Ethics Committee of Tabriz University of Medical Sciences approved this manuscript with the number IR.TBZMED. REC.1398.974. All patients' information is confidential.

This paper is the outcome of a specialty degree in the orthopedic thesis (thesis no.: 63378) approved by Tabriz University of Medical Sciences.

References

1. Compston JE, McClung MR, Leslie WD. Osteoporosis. *Lancet*. 2019;393(10169):364-76. doi: [10.1016/S0140-6736\(18\)32112-3](https://doi.org/10.1016/S0140-6736(18)32112-3). [PubMed: [30696576](https://pubmed.ncbi.nlm.nih.gov/30696576/)].
2. Lindahl H. Epidemiology of periprosthetic femur fracture around a total hip arthroplasty. *Injury*. 2007;38(6):651-4. doi: [10.1016/j.injury.2007.02.048](https://doi.org/10.1016/j.injury.2007.02.048). [PubMed: [17477925](https://pubmed.ncbi.nlm.nih.gov/17477925/)].
3. Zandi R, Karimi A, Sadighi M, Minator Sajjadi M, Okhovatpour MA, Ebrahimpour A, et al. Primary long distal fitting bipolar hemiarthroplasty for unstable intertrochanteric fracture in elderly patients. *J Orthop Spine Trauma*. 2020;4(3):42-7. doi: [10.18502/jost.v4i3.3070](https://doi.org/10.18502/jost.v4i3.3070).
4. Rayan F, Haddad F. Periprosthetic femoral fractures in total hip arthroplasty - a review. *Hip Int*. 2010;20(4):418-26. doi: [10.1177/112070001002000402](https://doi.org/10.1177/112070001002000402). [PubMed: [21157744](https://pubmed.ncbi.nlm.nih.gov/21157744/)].
5. Vanhegan IS, Malik AK, Jayakumar P, Ul Islam S, Haddad FS. A financial analysis of revision hip arthroplasty: The economic burden in relation to the national tariff. *J Bone Joint Surg Br*. 2012;94(5):619-23. doi: [10.1302/0301-620X.94B5.27073](https://doi.org/10.1302/0301-620X.94B5.27073). [PubMed: [22529080](https://pubmed.ncbi.nlm.nih.gov/22529080/)].
6. Moazen Jamshidi SMM, Razzaghof M, Mortazavi SJ. Decision making in femoral neck fractures: Internal fixation versus arthroplasty. *J Orthop Spine Trauma*. 2020;5(2):45-9. doi: [10.18502/jost.v5i2.3753](https://doi.org/10.18502/jost.v5i2.3753).
7. Dall'Oca C, Maluta T, Moscolo A, Lavini F, Bartolozzi P. Cement augmentation of intertrochanteric fractures stabilised with intramedullary nailing. *Injury*. 2010;41(11):1150-5. doi: [10.1016/j.injury.2010.09.026](https://doi.org/10.1016/j.injury.2010.09.026). [PubMed: [20932521](https://pubmed.ncbi.nlm.nih.gov/20932521/)].

8. Savin L, Barharosie C, Botez P. Periprosthetic femoral fractures-evaluation of risk factors. *Rev Med Chir Soc Med Nat Iasi*. 2012;116(3):846-52. [PubMed: 23272540].
9. Bhattacharyya T, Chang D, Meigs JB, Estok DM, Malchau H. Mortality after periprosthetic fracture of the femur. *J Bone Joint Surg Am*. 2007;89(12):2658-62. doi: 10.2106/JBJS.F.01538. [PubMed: 18056498].
10. Matharu GS, Pynsent PB, Dunlop DJ, Revell MP. Clinical outcome following surgical intervention for periprosthetic hip fractures at a tertiary referral centre. *Hip Int*. 2012;22(5):494-9. doi: 10.5301/HIP.2012.9760. [PubMed: 23112076].
11. Dorr LD, Faugere MC, Mackel AM, Gruen TA, Bognar B, Malluche HH. Structural and cellular assessment of bone quality of proximal femur. *Bone*. 1993;14(3):231-42. doi: 10.1016/8756-3282(93)90146-2. [PubMed: 8363862].
12. Nakaya R, Takao M, Hamada H, Sakai T, Sugano N. Reproducibility of the Dorr classification and its quantitative indices on plain radiographs. *Orthop Traumatol Surg Res*. 2019;105(1):17-21. doi: 10.1016/j.otsr.2018.11.008. [PubMed: 30594598].
13. Landis JR, Koch GG. The measurement of observer agreement for categorical data. *Biometrics*. 1977;33(1):159-74. [PubMed: 843571].
14. Sah AP, Thornhill TS, LeBoff MS, Glowacki J. Correlation of plain radiographic indices of the hip with quantitative bone mineral density. *Osteoporos Int*. 2007;18(8):1119-26. doi: 10.1007/s00198-007-0348-6. [PubMed: 17340218]. [PubMed Central: PMC2778043].
15. Noble PC, Alexander JW, Lindahl LJ, Yew DT, Granberry WM, Tullos HS. The anatomic basis of femoral component design. *Clin Orthop Relat Res*. 1988;(235):148-65. [PubMed: 3416522].
16. Noble PC, Box GG, Kamaric E, Fink MJ, Alexander JW, Tullos HS. The effect of aging on the shape of the proximal femur. *Clin Orthop Relat Res*. 1995;(316):31-44. [PubMed: 7634721].
17. Fessy MH, Seutin B, Bejui J. Anatomical basis for the choice of the femoral implant in the total hip arthroplasty. *Surg Radiol Anat*. 1997;19(5):283-6. doi: 10.1007/BF01637590. [PubMed: 9413072].
18. Laine HJ, Lehto MU, Moilanen T. Diversity of proximal femoral medullary canal. *J Arthroplasty*. 2000;15(1):86-92. doi: 10.1016/s0883-5403(00)91311-1. [PubMed: 10654468].
19. Husmann O, Rubin PJ, Leyvraz PF, de RB, Argenson JN. Three-dimensional morphology of the proximal femur. *J Arthroplasty*. 1997;12(4):444-50. doi: 10.1016/s0883-5403(97)90201-1. [PubMed: 9195321].
20. Khang G, Choi K, Kim CS, Yang JS, Bae TS. A study of Korean femoral geometry. *Clin Orthop Relat Res*. 2003;(406):116-22. doi: 10.1097/01.blo.0000030502.43495.c1. [PubMed: 12579009].
21. Rubin PJ, Leyvraz PF, Aubaniac JM, Argenson JN, Esteve P, de Roguin B. The morphology of the proximal femur. A three-dimensional radiographic analysis. *J Bone Joint Surg Br*. 1992;74(1):28-32. doi: 10.1302/0301-620X.74B1.1732260. [PubMed: 1732260].
22. Diamantopoulos AP, Hoff M, Skoie IM, Hochberg M, Haugeberg G. Short- and long-term mortality in males and females with fragility hip fracture in Norway. A population-based study. *Clin Interv Aging*. 2013;8:817-23. doi: 10.2147/CIA.S45468. [PubMed: 23861581]. [PubMed Central: PMC3704300].