

Severely Comminuted Transolecranon Fracture Fixation with the Help of Medial Humerus Anatomical Plate: A Case Report and Educational Corner

Seyed Peyman Mirghaderi¹, Sadula Sharifpour², Amirhossein Ghaseminejad Raeini¹, Maryam Salimi¹, Alireza Moharrami², Seyed Hadi Kalantar^{1,3,*}

¹ Medical Student, Joint Reconstruction Research Center, Imam Khomeini Hospital Complex, Tehran University of Medical Sciences, Tehran, Iran

² Resident, Joint Reconstruction Research Center, Imam Khomeini Hospital Complex, Tehran University of Medical Sciences, Tehran, Iran

³ Assistant Professor, Joint Reconstruction Research Center, Imam Khomeini Hospital Complex, Tehran University of Medical Sciences, Tehran, Iran

*Corresponding author: Seyed Hadi Kalantar; Joint Reconstruction Research Center, Imam Khomeini Hospital Complex, Tehran University of Medical Sciences, Tehran, Iran. Tel: 21-66581586, Email: hadikalantar4@gmail.com

Received: 19 February 2022; Revised: 24 April 2022; Accepted: 11 May 2022

Abstract

Background: Transolecranon fracture is an unstable intra-articular injury in the elbow caused by high-energy trauma. Here, we introduce a medial humerus plate for severely comminuted transolecranon fracture.

Case Report: This article presents the case of a 29-year-old man who had a severely comminuted transolecranon fracture due to a motorcycle accident. A dorsal longitudinal approach was used in order to reach the fracture site. An olecranon anatomical plate and a medial humerus plate were applied for fixation, a new treatment method. The range of motion (ROM) was complete at a two-month follow-up, and the Mayo Elbow Performance Score (MEPS) was obtained 100 with no signs of complications.

Conclusion: Despite the several methods available for fixing transolecranon fractures, using the medial humerus plate, especially in severe comminution, can yield acceptable results. It should be considered in future studies to prove its efficacy in this type of fracture.

Keywords: Elbow; Elbow Joint; Fracture Dislocation; Olecranon Process

Citation: Mirghaderi SP, Sharifpour S, Ghaseminejad Raeini A, Salimi M, Moharrami A, Kalantar SH. **Severely Comminuted Transolecranon Fracture Fixation with the Help of Medial Humerus Anatomical Plate: A Case Report and Educational Corner.** *J Orthop Spine Trauma* 2022; 8(3): 97-100.

Background

Elbow fracture-dislocations are rare conditions that are demanding for surgeons to treat (1). Transolecranon fracture-dislocation is a type of proximal ulnar intra-articular fracture which leads to ulno-humeral joint instability. It is defined as an olecranon process and trochlear notch fracture and dislocation to the anterior (2).

One of the most important differential diagnoses of this type of injury is a Monteggia fracture. The main distinction between them is that the proximal radioulnar joint remains intact in transolecranon dislocations. In addition, transolecranon fractures do not generally cause ligamentous injury despite anterior dislocation of the radiocapitellar joint. These fractures rarely occur in the general population and usually happen following a high-energy trauma (such as a motorcycle accident) (3-6). There are also considerable differences in terms of surgery. In transolecranon fractures, the essential part of the treatment is to preserve the trochlear notch and make a proper reduction in case of dislocation. However, in Monteggia fractures, the primary purpose of surgery is the proper alignment of the ulna throughout the reduction process of the proximal radioulnar joint.

After reviewing the literature on different surgical methods for transolecranon injuries, this article discusses about a novel fixation method - using medial humerus anatomical plate - to treat severely comminuted transolecranon fracture (7-11).

A) Non-Operative Treatment

Most fractures can be treated non-surgically, depending on specific conditions. This method has been studied in olecranon fractures without elbow instability and indicates successful results. However, in transolecranon fractures,

treatment choice is surgery and open fixation (12). According to a case report written by Arain et al., a 7-year-old child was treated with a long arm cast for a month and then a splint for two weeks. The range of motion (ROM) of the elbow was full, and the patient was treated entirely. Still, there is lacking evidence for the non-operative approach in these types of fractures. It is preferred when the patient cannot tolerate the surgical procedure (13).

B) Surgical Techniques

To do the operation, general anesthesia or supraclavicular block is utilized to anesthetize patients. During the surgical procedure, a direct posterior approach is usually applied. An incision is made in the midline and, while the triceps insertion remains intact, extensor carpi ulnaris (ECU) and anconeus are elevated to expose the fracture site (Figure 1). Several techniques to fix the fracture include tension band wiring, reconstruction plates, etc. (3, 12).

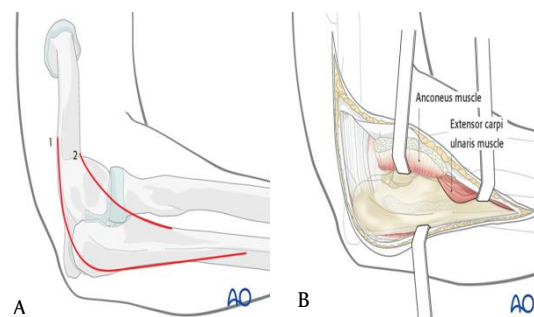


Figure 1. A: Direct posterior approach of initial incision (line 1) in order to expose the fracture area - the incision starts from a few centimeters upper than olecranon's tip; B: Complete ulna exposure (image is from AO foundation, <https://surgeryreference.aofoundation.org> - Access date: 2021/10/06)



B-1) Tension Band Wiring: In 2005, Mortazavi et al. retrospectively reviewed the medical records of transolecranon fracture cases in their hospital. Finally, 8 cases with a mean age of 35 years were examined. In one patient, tension band wiring with interfragmentary screws and Kirschner wires (K-wires) was used. After 12 weeks of surgery, the fracture site nonunion was noted, and the wires were loosened. He had to undergo revision surgery three years later, and this time, a reconstruction plate was implanted for him (1). In a study conducted by Mouhsine et al., for 7 cases of the sample size, fixation with tension band wiring was adopted. Three patients developed nonunion and underwent surgery again. The outcomes of the treatment were not entirely satisfactory (14).

On the other hand, in a case reported by Yamaura et al., an operation was done on a 7-year-old child with a transolecranon fracture due to an accident with a posterior approach and 1.6-mm K-wire, revealing promising results. The patient had a full ROM during follow-up sessions, and no joint deformity was noted (15). Besides, Lindenhovius et al. case series based on olecranon fractures indicated that this method became handy in three patients with transolecranon surgery. In accordance with the functional indexes for elbow injuries, such as the Mayo Elbow Performance Score (MEPS) and the Broberg and Morrey rating system, the outcome was excellent in two of them and good for the other one (16). According to a recent study on transolecranon fractures in children by Yang et al., tension band wiring seems to produce favorable outcomes in this age group. The MEPS was between 85 and 100 in four fractures fixed by this technique (17).

B-2) Tension Suture: Tension suture is not a common technique for fixing this type of fracture. In the study of Doornberg et al., just one patient underwent this kind of operation, demonstrating acceptable outcomes (8).

B-3) Dynamic Compression Plate (DCP): This particular technique is popular amongst orthopedic surgeons. In a case study in 1997, Ring et al. focused on the side effects and degree of functional improvement after fixation. Nine patients were treated with 3.5-mm DCPs. Elbow function measured by the Broberg and Morrey index was excellent, and no specific complications were observed (2). In the study by Doornberg et al., six patients' fractures were fixed by 3.5-mm DCPs. Their functional score was determined either good or excellent for all of them (8). Moreover, four clinical cases reviewed by Lindenhovius et al. demonstrated promising results based on the Broberg and Morrey index and Mayo Elbow Performance Index (MEPI) (16).

B-4) Reconstruction Plate: After anatomical plates, reconstruction plates are perhaps the most common instrument employed to fix transolecranon fractures. In Mortazavi et al. study, the surgical technique used in seven patients was 3.5-mm reconstruction plates with 8-10 screws put dorsal to the fracture site. The Broberg and Morrey index was excellent in two of them and good in the rest (1). In addition, in a retrospective case series study conducted by Lemsanni et al., in all 15 sample cases, fixation was performed with 3.5-mm reconstruction plates. Follow-up results were excellent in 11 cases and good in 4 of them based upon the Broberg and Morrey index. Complications were observed in only three patients, elbow stiffness, wound infection, and arthritis, separately (18).

Nevertheless, according to Yang et al. research, fixation with reconstruction plates is less effective in children with transolecranon fractures. According to the article results, five patients were treated with this technique, three of whom got a poor MEPS (45 and 55) in long-term follow-up (17).

B-5) Semitubular and 1/3 Tubular Plate: Tubular plates are another device applied to treat transolecranon fractures (more unusual than others). In their study, Ring et al. reviewed four fractures fixed with this method. Overall joint function was acceptable, hinged upon the Broberg and Morrey index (2). In the study of Lindenhovius et al., two patients were treated with one-third tubular plates, one of which failed, and revision surgery was required (16).

B-6) Anatomic Pre-Contoured Plate: Indeed, among orthopedic surgeons, one of the most popular surgical procedures is the fixation with pre-contoured plates (or anatomical plates of the olecranon). In their study, Haller et al. reviewed the records of patients who suffered from olecranon fractures and referred to their hospital from 2005 to 2018. Thirty-five patients were selected as a sample. The fractures were all fixed with 3.5-mm pre-contoured plates. Quick Disabilities of Arm, Shoulder, and Hand (QuickDASH) index was utilized to track patients' elbow function. Radiographic images of their elbow were also taken to evaluate for osteoarthritis (OA) (as a vital complication). The mean QuickDASH score was 9 (range: 0 to 59; 80% of cases completed the questionnaire), meaning an excellent joint recovery in the majority of them. Thirteen subjects had evidence of OA in their radiographs. No one had to undergo revision surgery (19).

Recently, Luengo-Alonso et al. conducted a study researching the treatment outcome of transolecranon fractures. The sample of this retrospective case study included 15 patients. All of their fractures were fixed using the anatomical plates of the olecranon. Outcomes were measured based on the Disabilities of Arm, Shoulder, and Hand (DASH) and MEPI scores. Probable complications were also asked from the patients. At a one-year follow-up, the average DASH score of the cases was 36.68 (range: 30 to 46), and the mean MEPI was 100. No complications (such as infection, nonunion, or nerve damage) were noted. Just in one patient, mild heterotopic ossification (HO) occurred. Overall, the patients' functional outcomes remained favorable (20).

Case Report

A 29-year-old man was admitted to the emergency department with an open elbow fracture due to a motorcycle accident. Further evaluations revealed an anterior transolecranon fracture-dislocation accompanied by a laceration leading to rupture of the flexor carpi ulnaris (FCU) and ECU muscles (Figure 2). Neurological examinations and arterial pulses were normal.

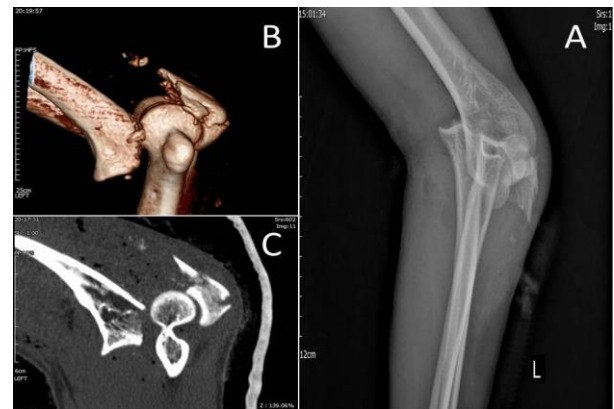

Figure 2. The patient fracture in different types of imaging; A: Radiograph, B: Three-dimensional computed tomography (3D CT) scan, C: Simple CT scan

Due to the foreign material contamination of the patient's laceration, debridement and irrigation were performed in the emergency department, and a course of antibiotic treatment was prescribed for him. He was then taken to the operating room. After reduction, the olecranon was fixed provisionally with multiple pins (Figure 3A). The initial incision was made on the patient's elbow with a dorsal longitudinal approach (Figure 3B). Because of severe comminution, especially on the medial side, the treatment choice for this patient was applying an olecranon anatomical plate (posterior to the fracture) and a medial humerus anatomical plaque (medial to the fracture) along with tension band wiring, which is considered a novel usage of the medial humerus anatomical plaque (Figure 3C and 3D). Finally, after repairing the FCU and ECU muscles, the wound was irrigated again and sutured in multiple layers.

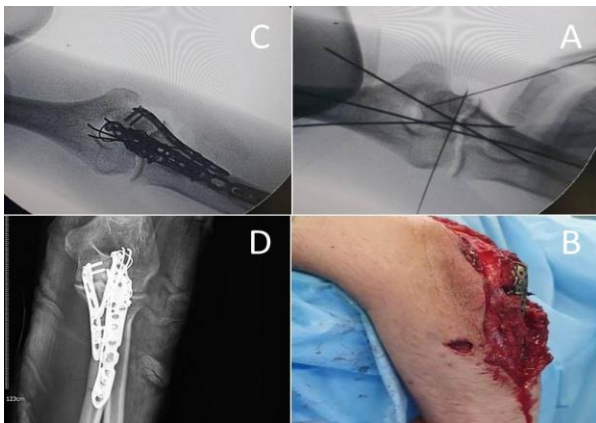


Figure 3. A: Provisional pin fixation after anatomical reduction; B: An intra-operative picture; C and D: Fixation with olecranon and medial humerus plate

The patient wore a splint for a week following the operation. From the second week, a bandage was placed on the elbow along with elastic bands. Passive movements began, followed by the active assisted and active movements. To prevent HO, indomethacin 25 mg three times daily was prescribed for him. At a two-month follow-up, the patient underwent ten sessions of physiotherapy to recover his weak muscles. After that, he returned to his job, and his elbow's ROM was completely recovered. MEPS was measured 100, representing an excellent outcome. No complications such as nonunion, infection, or joint stiffness were noticed (Figure 4).

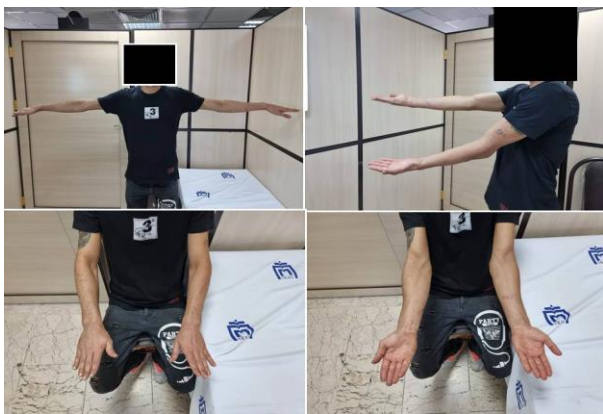

Figure 4. Patient elbow's full range of motion (ROM) in the follow-up session

Discussion

Humerus anatomical plates are mainly utilized to fix distal humeral fractures (also known as distal humerus locking plates) (21). They have two types: lateral and medial, which are employed to treat epicondylar and supracondylar fractures on each side (22, 23). Medial plates have also been used in coronoid process injuries (24). However, there is no evidence that these plates can also be effective for transolecranon fractures. The length and curvature of the plate, as well as the severe fragmentation of the fracture in this case (especially on the medial side), were the factors that persuaded us to use the medial humerus plate along with the olecranon anatomical plate to fix it.

As mentioned, there are several methods of fixation for the treatment of transolecranon fractures. We believe that using the medial humerus anatomical plates in the medial side of the fracture is a perfect fixation choice, especially when there is comminution. Further, the joint's stability must be good enough to start passive movements as soon as possible. In this case, we slowly reduced the fracture anatomically without using any special maneuvers, and the clinical outcome was excellent. This technique may be a new preference for the management of these types of fractures. More studies should be conducted to prove it.

Conclusion

The use of the medial humerus plate, especially in severe comminution, is an acceptable method for fixing transolecranon fractures despite several available methods. The joint's stability must be good enough to start passive movements as soon as possible.

Conflict of Interest

The authors declare no conflict of interest in this study.

Acknowledgements

None.

References

- Mortazavi SM, Asadollahi S, Tahririan MA. Functional outcome following treatment of transolecranon fracture-dislocation of the elbow. *Injury*. 2006;37(3):284-8. doi: [10.1016/j.injury.2005.10.028](https://doi.org/10.1016/j.injury.2005.10.028). [PubMed: 16442109].
- Ring D, Jupiter JB, Sanders RW, Mast J, Simpson NS. Transolecranon fracture-dislocation of the elbow. *J Orthop Trauma*. 1997;11(8):545-50. doi: [10.1097/00005131-199711000-00001](https://doi.org/10.1097/00005131-199711000-00001). [PubMed: 9415859].
- Cho CH, Kim DH, Na SS, Choi BC, Kim BS. Trans-olecranon fracture-dislocations of the elbow: A systematic review. *Diagnostics (Basel)*. 2020;10(12):1058. doi: [10.3390/diagnostics10121058](https://doi.org/10.3390/diagnostics10121058). [PubMed: 33291269]. [PubMed Central: PMC7762091].
- Flinterman HJ, Doornberg JN, Guitton TG, Ring D, Goslings JC, Kloen P. Long-term outcome of displaced, transverse, noncomminuted olecranon fractures. *Clin Orthop Relat Res*. 2014;472(6):1955-61. doi: [10.1007/s11999-014-3481-5](https://doi.org/10.1007/s11999-014-3481-5). [PubMed: 24522384]. [PubMed Central: PMC4016441].
- Wong JC, Getz CL, Abboud JA. Adult monteggia and olecranon fracture dislocations of the elbow. *Hand Clin*. 2015;31(4):565-80. doi: [10.1016/j.hcl.2015.06.006](https://doi.org/10.1016/j.hcl.2015.06.006). [PubMed: 26498546].
- Hedayat E, Apostolou N, Mohammadi MA, Nabian MH. Step by step approach to interpretation of pediatric elbow radiography. *J Orthop Spine Trauma*. 2020;5(1):7-11. doi: [10.18502/jost.v5i1.3352](https://doi.org/10.18502/jost.v5i1.3352).
- Chan K, King GJ, Faber KJ. Treatment of complex elbow fracture-dislocations. *Curr Rev Musculoskelet Med*. 016;9(2):185-9. doi: [10.1007/s12178-016-9337-8](https://doi.org/10.1007/s12178-016-9337-8). [PubMed: 27111111].

- 26984334]. [PubMed Central: PMC4896880].
8. Doornberg J, Ring D, Jupiter JB. Effective treatment of fracture-dislocations of the olecranon requires a stable trochlear notch. *Clin Orthop Relat Res.* 2004;(429):292-300. doi: [10.1097/01.blo.0000142627.28396.cb](https://doi.org/10.1097/01.blo.0000142627.28396.cb). [PubMed: 15577501].
 9. Hajivandi S, Dacheh A, Salimi A, Mamaghani HJ, Mirghaderi SP, Dehghani J, et al. Comparison of the separate and combined effects of physiotherapy treatment and corticosteroid injection on the range of motion and pain in nontraumatic rotator cuff tear: A randomized controlled trial. *Adv Orthop.* 2021;2021:6789453. doi: [10.1155/2021/6789453](https://doi.org/10.1155/2021/6789453). [PubMed: 34733561]. [PubMed Central: PMC8560293].
 10. Salimi M, Dehghani J, Gerami MH. Efficacy of elastic intramedullary nails in treating axially unstable femur fracture in children. *Pak J Med Health Sci.* 2021;15(1):572-6
 11. Sharafi M, Presedo A, Rabie H, Nabian MH. Flexion-type supracondylar humerus fracture: A review on reduction techniques. *J Orthop Spine Trauma.* 2020;4(3):54-8. doi: [10.18502/jost.v4i3.3079](https://doi.org/10.18502/jost.v4i3.3079).
 12. Luchetti TJ, Abbott EE, Baratz ME. Elbow fracture-dislocations: determining treatment strategies. *Hand Clin.* 2020;36(4): 495-510. doi: [10.1016/j.hcl.2020.07.011](https://doi.org/10.1016/j.hcl.2020.07.011). [PubMed: 33040962].
 13. Arain AR, Haddad S, Anderson M, Murtaza H, Rosenbaum A. Isolated pediatric transolecranon fracture-dislocation of the elbow managed nonoperatively: A case report and review of literature. *Clin Case Rep.* 2019;7(7):1435-8. doi: [10.1002/ccr3.2268](https://doi.org/10.1002/ccr3.2268). [PubMed: 31360506]. [PubMed Central: PMC6637335].
 14. Mouhsine E, Akiki A, Castagna A, Cikes A, Wettstein M, Borens O, et al. Transolecranon anterior fracture dislocation. *J Shoulder Elbow Surg.* 2007;16(3):352-7. doi: [10.1016/j.jse.2006.07.005](https://doi.org/10.1016/j.jse.2006.07.005). [PubMed: 17188909].
 15. Yamaura K, Inui A, Mifune Y, Nishimoto H, Kataoka T, Kurosawa T, et al. Anterior transolecranon fracture dislocation with an associated avulsion fracture of coronoid process of ulna in a child: A case report. *JSES Int.* 2021;5(1):9-12. doi: [10.1016/j.jseint.2020.10.00](https://doi.org/10.1016/j.jseint.2020.10.00). [PubMed: 33554156]. [PubMed Central: PMC7846680].
 16. Lindenhovius AL, Brouwer KM, Doornberg JN, Ring DC, Kloen P. Long-term outcome of operatively treated fracture-dislocations of the olecranon. *J Orthop Trauma.* 2008;22(5): 325-31. doi: [10.1097/BOT.0b013e31817283f7](https://doi.org/10.1097/BOT.0b013e31817283f7). [PubMed: 18448986].
 17. Yang Z, Feng C, Bian Z, Lu M, Zhou D. Trans-olecranon fracture-dislocation of the elbow in children. *Int Orthop.* 2021;45(8): 2025-31. doi: [10.1007/s00264-021-05010-8](https://doi.org/10.1007/s00264-021-05010-8). [PubMed: 33846848].
 18. Lemsanni M, Najeb Y, Chafik R, Madhar M, Elhaoury H. Transolecranon fracture-dislocations of the elbow: A case series of 15 patients. *Int J Res Orthop.* 2020;6(6):1285-90. doi: [10.18203/jissn.2455-4510.IntJResOrthop20204598](https://doi.org/10.18203/jissn.2455-4510.IntJResOrthop20204598).
 19. Haller JM, Hulet DA, Hannay W, Cardon J, Tashjian R, Beingsner D. Patient outcomes after transolecranon fracture-dislocation. *J Am Acad Orthop Surg.* 2021;29(3):109-15. doi: [10.5435/JAAOS-D-20-00254](https://doi.org/10.5435/JAAOS-D-20-00254). [PubMed: 32433427].
 20. Luengo-Alonso G, Garcia LL, Jimenez D, V, Ferrero RJ, Porras Moreno MA, Cecilia LD. Trans-olecranon fracture dislocations: How should we treat them? *Injury.* 2021;52(Suppl 4):S131-S136. doi: [10.1016/j.injury.2021.02.058](https://doi.org/10.1016/j.injury.2021.02.058). [PubMed: 33642078].
 21. O'Driscoll SW. Optimizing stability in distal humeral fracture fixation. *J Shoulder Elbow Surg.* 2005;14(1 Suppl S):186S-94S. doi: [10.1016/j.jse.2004.09.033](https://doi.org/10.1016/j.jse.2004.09.033). [PubMed: 15726080].
 22. Sanchez-Sotelo J, Torchia ME, O'Driscoll SW. Complex distal humeral fractures: Internal fixation with a principle-based parallel-plate technique. *J Bone Joint Surg Am.* 2007;89(5): 961-9. doi: [10.2106/JBJS.E.01311](https://doi.org/10.2106/JBJS.E.01311). [PubMed: 17473132].
 23. Zalavras CG, Papasoulis E. Intra-articular fractures of the distal humerus-a review of the current practice. *Int Orthop.* 2018;42(11):2653-62. doi: [10.1007/s00264-017-3719-4](https://doi.org/10.1007/s00264-017-3719-4). [PubMed: 29404666].
 24. Lor KKH, Toon DH, Wee ATH. Buttress plate fixation of coronoid process fractures via a medial approach. *Chin J Traumatol.* 2019;22(5):255-60. doi: [10.1016/j.cjtee.2019.05.005](https://doi.org/10.1016/j.cjtee.2019.05.005). [PubMed: 31492574]. [PubMed Central: PMC6823711].