

The Role of Spinopelvic Parameters in Total Hip Arthroplasty: A Current Concept Review

Mir Mansour Moazen Jamshidi¹, Alireza Moharrami², Seyed Peyman Mirghaderi³, Sadula Sharifpour², Amir Reza Mafi⁴, Seyed Mohammad Javad Mortazavi^{5,*}

¹ Assistant Professor, Department of Orthopedic Surgery, School of Medicine, Zanjan University of Medical Sciences, Zanjan, Iran

² Resident, Joint Reconstruction Research Center, Tehran University of Medical Sciences, Tehran, Iran

³ Students' Scientific Research Center (SSRC), Tehran University of Medical Sciences, Tehran, Iran

⁴ General Practitioner, Joint Reconstruction Research Center, Tehran University of Medical Sciences, Tehran, Iran

⁵ Professor, Joint Reconstruction Research Center, Imam Khomeini Hospital Complex, Tehran University of Medical Sciences, Tehran, Iran

*Corresponding author: Seyed Mohammad Javad Mortazavi; Joint Reconstruction Research Center, Imam Khomeini Hospital Complex, Tehran University of Medical Sciences, Tehran, Iran. Tel: 21-61192767, Email: smjmort@yahoo.com

Received: 02 February 2022; Revised: 14 April 2022; Accepted: 16 May 2022

Abstract

The spine, pelvis, and hip are three anatomic structures that tightly interact to create spinopelvic mobility and harmony. Orthopaedic surgeons, both spine and hip specialists, must have a complete awareness of this concept. Recently, the literature has placed great emphasis on paying attention to these parameters in the preoperative planning of the total hip arthroplasty (THA). We could distinguish between balanced and unbalanced pelvis and spine with spinopelvic parameters and therefore, we could diagnose the spinopelvic stiffness that is important in preventing complications following THA. This review briefly introduces the importance of spinopelvic parameters and their critical role in THA outcome. Treatment algorithms are also provided based on the most recent studies.

Keywords: Pelvic Bones; Diagnostic Imaging; Spine; Total Hip Arthroplasty; Postural Balance; Physiology

Citation: Moazen Jamshidi MM, Moharrami A, Mirghaderi SP, Sharifpour S, Mafi AR, Mortazavi SMJ. **The Role of Spinopelvic Parameters in Total Hip Arthroplasty: A Current Concept Review.** *J Orthop Spine Trauma* 2022; 8(2): 40-3.

Background

Recently, spinopelvic mobility has been considered by the literature which is necessary for normal posture and movement (1-5). In patients with balanced and normal mobility spine, distinctive changes of spinopelvic sagittal parameters are expected. This adaptation that occurs from standing to the sitting position always happens even with abnormal baseline parameters (6) (Figure 1); typically, sacrum moves posteriorly, lumbar lordosis (LL) decreases, and acetabular anteversion (AA) increases (7). The hip is involved in part of the movement in combination with the pelvis and spine. The bending of the hip is about 55-70 degrees, posterior tilt of pelvis increases to 20 degrees, and the LL decreases approximately 20 degrees (2).

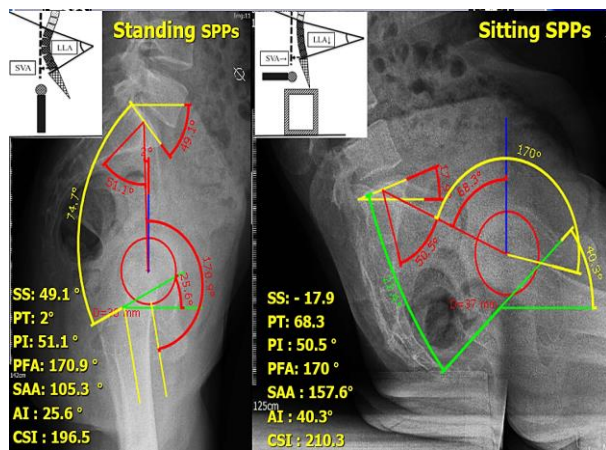


Figure 1. The changing in spinopelvic parameters from standing to sitting

Similarly, the posterior tilt of the pelvis influences the sacral slope (SS) and reduces it in the same amount (3), and each degree of rearward movement of the pelvis [pelvic tilt (PT) increase] results in a 0.7°-0.8° AA increase (8, 9). In changing the position, these parameters change in relation to each other, making the spinopelvic movements. It is crucial to be aware that the spinopelvic parameters are dynamic and change in different positions to ensure movement and posture. Spinopelvic mobility has important effect on the hip joint motion and it is important to address the spinopelvic motion and parameters in preoperative planning of total hip arthroplasty (THA). The literature had an great emphasis on the spinopelvic motion and diagnosis of any spinopelvic abnormality such as stiffness, dislocations, and balancing (10). This review briefly introduces the importance of spinopelvic parameters and their critical role in THA outcome. Treatment algorithms are also provided based on the most recent studies.

THA and Spinopelvic Mobility

The spinopelvic mobility is influenced by degeneration of the hip joint or spine or spinal fusion surgery (11). There is increasing degenerative disease with aging in developed societies with concurrent hip and spine degeneration in many people, called hip-spine syndrome (12). THA was performed for many patients with lumbar fusion (13, 14). Spinopelvic mobility is mandatory for acetabular functional orientation in THA surgery. Spinopelvic mobility and implant position should be given essential attention before the THA to achieve acceptable outcomes and avoid complications following the surgery (15). Regardless of recent progression of THA outcome, dislocation and instability after THA remain a significant concern. Abnormal spinopelvic parameters could give us a logical



clue to find out these complications with unknown etiology. It has been proved that the dislocation rate is higher in THA patients with concurrent lumbosacral problems, as high as 7.5% in 2-year follow-up (16). In addition, prior lumbar fusion is associated with inferior results in patient-reported outcome measures (PROMs) (17).

Spinopelvic Parameters

PT: PT is the angle between the line connecting the middle point of S1 superior endplate to the femoral head center and the vertical axis. This parameter indicates the relative rotation of the pelvis to hip joint (18). The normal value is 13° in the standing position that increases in the sitting position due to posterior PT (Figure 2A) (19). AA angle increases 0.7°-0.8° by an increase in one degree of PT (9).

Pelvic Incidence (PI): PI is the angle between the line perpendicular to the midpoint of S1 superior endplate and the line that starts from this point to the center of the femoral head (average = 52 ± 10 degrees) (19). This anatomical parameter is constant in adults in various positions, whether sitting or standing (3). Sum of PT and SS results in PI (3). PI amount is related to the pelvic width, LL, and SS, and higher measures are a risk factor for degenerative/dysplastic spondylolisthesis (Figure 2B) (20).

SS: SS is the angle between the S1 superior endplate and the horizontal axis. The normal value is 42° (19). The S1 superior endplate is indicative for LL, and the SS increases with an increase in LL. SS increases when transmitting from the sitting position (30°) to standing (50°), and this change is defined as ΔSS. By delineating the ΔSS, we can estimate the spinopelvic motility (Figure 2C) (21).

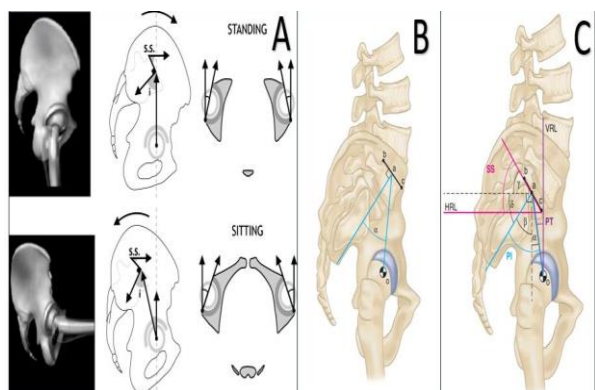


Figure 2. Pelvic tilt (PT) changing (A), pelvic incidence (PI) (B), and sacral slope (SS) (C)

Regarding SS and PI variance, high values increase the shear force on the lumbosacral junction (especially pars L5). Adversely, low SS and PI impose a nutcracker effect on the pars (Figure 3) (22).

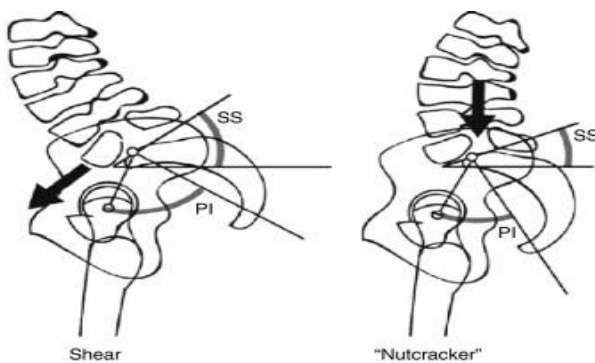


Figure 3. The shear and nutcracker spinopelvic postures introduced by Labelle et al. (20)

Anteinclination (AI): AI is the angle between the horizontal axis and the line joining the anterior and posterior acetabular wall in the sagittal plane (23). The changes in inclination and anteversion are in line with each other, and both of them influence AI. In transmitting the position, both anteversion and inclination are changed, thus changing AI (24). The average of AI in standing is 30° (decrease), and sitting is 50° (increase) (24). Each degree of AI increase causes a 0.7° increase in PI. This parameter accommodates the necessary hip flexion and internal rotation (Figure 4A) (24).

Pelvic Femoral Angle (PFA): PFA is the sagittal angle between lines starting from the center of the femoral head to the midpoint of the S1 superior endplate and the femoral stem (25). This parameter demonstrates the relative position of the femur to the pelvis and is equal to 180° in standing and 125° in sitting position (Figure 4B).

Anterior Plane PT (APPT): APPT is the angle between the vertical line and the line joining two superimposed anterior superior iliac spine (ASIS) and the anterior edge of the pubic symphysis (shows the rotation of the pelvis in the sagittal surface) (Figure 4C).

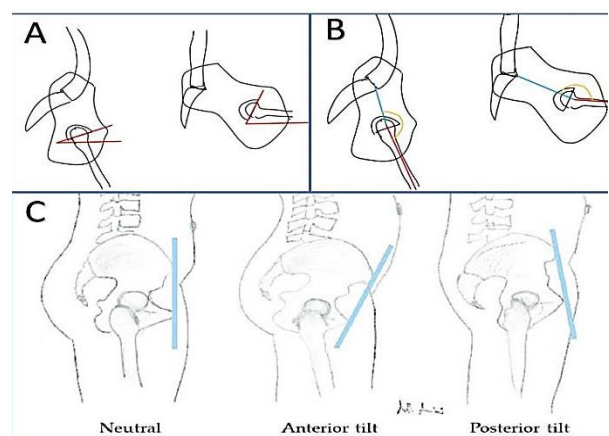


Figure 4. Femoral anteinclination (AI) (A), pelvic femoral angle (PFA) (B), anterior plane pelvic tilt (APPT) (C)

Spinopelvic Mobility and Balance

Spinopelvic parameters are helpful assessment tools to assess balance in patients with spinal deformity. The spine and pelvis have compensatory mechanisms to preserve the hips' balance, whether natural or artificial hip joint (6). PI, a sum of PT and SS, is the main entity that indicates the proper sagittal balance of the spine. PI is a specific anatomical parameter with a constant value; therefore, changes in PT and SS are in opposite directions aiming to sustain body balance (6). Besides, change in SS is correlated with LL changes (21). In this regard, also it has been proved that, generally, the LL is within 10° of PI, and being out of this range (PI-LL mismatch > 10°) suggests deformity and sagittal unbalance (6, 7). PI minus LL > 10° is suggestive for the flatback spinal deformity (21). As a result, stooped posture will be probable, or the patient normally stands with the help of posterior PT (increased PT). Homma et al. showed compensatory posterior PT and, therefore, greater functional cup anteversion in this situation, thus are at the higher risk of posterior impingement and anterior dislocation while extending the hip (7). Phan et al. considered PI-LL mismatch < 10° and PT < 25° as sagittal spinal balance (6). Besides, the normal spinopelvic mobility is defined as 10° < ΔSS < 30° (average 20°) when turning from standing to sitting position (11).

More than this amount is considered hypermobility, and $\Delta SS < 10^\circ$ is considered stiffness (23). Degenerative changes in the spine and hip due to senescence negatively impact spinopelvic mobility and balance (11).

Hip surgeons seek to classify patients prior to the surgery and consider a different approach to them. Phan et al. explain four combination models of spinal flexibility and balance – “Hip-Spine Classification in THA” (Table 1) (6):

Table 1. The treatment considerations of any type of spinopelvic motions		
Treatment considerations	Balanced	Unbalanced
Flexible	Cup anteversion 5° - 25°	First option: Spinal realignment surgery, then THA with cup anteversion from 15° to 25° Second option: Primary THA with decreased cup anteversion
Rigid	Cup anteversion 15° - 25°	First option: Spinal realignment surgery, then THA with cup anteversion from 15° to 25° Second option: Primary THA with decreased cup anteversion

THA: Total hip arthroplasty

A. Flexible and balanced (F/B): Normal spinopelvic mobility, with no spine abnormality. In these patients, AA should be in the safe zone of 5° to 25° , which warrants appropriate range of motion (ROM) and slight impingement (6).

B. Flexible and unbalanced (F/U): Patients due to spine abnormalities, such as neuromuscular or post-laminectomy kyphosis, compensate through posterior PT in standing position which results in flatback spinal deformity. In this condition, increased AA observed in standing results in posterior impingement/anterior dislocation risk. In sitting, the pelvis has full mobility and goes to extension due to proper mobility, yielding a normal AA angle with minimal abnormality (26, 27).

Two treatment options exist for F/U patients: fixation surgery to reconstruct the spinal deformity, which turns the patient from F/U to rigid and balanced (R/B) with more predictable outcomes of THA (28), and alternatively, implanting the cup in an appropriate position to balance the spine (decreased AA during cup implantation).

C. R/B: Limited mobility as in degenerated or fused spine (in stuck stand posture). In these patients, regardless of the balanced sagittal spine in a standing position, the compensation mechanisms are inadequate in position transition. Therefore, the AA angle will not increase in sitting position, which is abnormal, causing a disturbance in flexion and risk of anterior impingement/posterior dislocation (6). All in all, the placed cup in THA should have more anteversion to counteract the mentioned mechanism. The recommended AA angle is 15° - 25° that provides optimal ROM and prevents dislocation/impingement (6).

D. Rigid and unbalanced (R/U): Unbalanced spine lacking compensatory mechanism due to rigidity in conditions like extended fusion or ankylosis (stuck sit). In these patients with a flatback spine, the pelvis is retroverted and AA increases. This structure yields more ROM of flexion and minor extension in standing that causes a higher risk of posterior impingement and anterior dislocation. In sitting position, AA amount replicates the expected sitting AA with slight abnormality.

Two treatment options exist for R/U patients: performing spine correction surgery, turning the patient to the R/B category, or doing THA implant the acetabular cup implant into a position that simulates balanced parameters (28). Both R/U and F/U patients who underwent THA without spinal realignment surgery and then proceeded with spinal

surgery might need revision hip surgery to re-align cup position based on the new condition.

Stiffness

Other studies revealed that non-stiff or mobile spinopelvic (normal and hyper-mobile) is compatible with different positions of acetabular components, instability, and impingement (23, 29). They recommend that performing routine surgery preserves the safe anteversion and inclination angle, $15^\circ \pm 10^\circ$ and $40^\circ \pm 10^\circ$, respectively (23, 29). Stiff spinopelvic cases are categorized into two groups based on their acetabular position:

A. Stuck standing: Posterior tilt (horizontal acetabular position) at risk of anterior impingement and posterior dislocation

B. Stuck sitting: Anterior tilt at risk of posterior impingement and anterior dislocation

The ultimate goal for cup implantation is 45° - 50° inclination, 20° - 25° anteversion with 35° - 40° combined anteversion (23, 29).

Conclusion

Several pieces of evidence exist for higher risk of complications after THA, e.g., instability and dislocation, in a patient with spinal abnormalities, including lumbar fusion, spinopelvic mobility fracture, and spinal deformity (21). In this regard, perceiving the spinopelvic parameters and appropriate preoperative consideration is mandatory for achieving good outcomes after THA. These patients should undergo evaluation for spine balance and appropriate motility before the THA (21). Surgeons seek to install stable constructs with minimum risk of instability, dislocation, and wear. Adjusted anteversion and inclination of the cup while insertion in THA can repair the imbalance drawbacks (29). Surgeons must consider spinopelvic classification, prior pathologies, and risk factors that are paramount for arthroplasty.

Conflict of Interest

The authors declare no conflict of interest in this study.

Acknowledgements

None.

References

- Dorr LD, Malik A, Wan Z, Long WT, Harris M. Precision and bias of imageless computer navigation and surgeon estimates for acetabular component position. *Clin Orthop Relat Res.* 2007;465:92-9. doi: [10.1097/BLO.0b013e3181560c51](https://doi.org/10.1097/BLO.0b013e3181560c51). [PubMed: [17693877](https://pubmed.ncbi.nlm.nih.gov/17693877/)].
- Innmann MM, Merle C, Gotterbarm T, Ewerbeck V, Beaulé PE, Grammatopoulos G. Can spinopelvic mobility be predicted in patients awaiting total hip arthroplasty? A prospective, diagnostic study of patients with end-stage hip osteoarthritis. *Bone Joint J.* 2019;101-B(8):902-9. doi: [10.1302/0301-620X.101B8.BJJ-2019-0106.R1](https://doi.org/10.1302/0301-620X.101B8.BJJ-2019-0106.R1). [PubMed: [31362559](https://pubmed.ncbi.nlm.nih.gov/31362559/)].
- Legaye J, Duval-Beaupère G, Hecquet J, Marty C. Pelvic incidence: A fundamental pelvic parameter for three-dimensional regulation of spinal sagittal curves. *Eur Spine J.* 1998;7(2):99-103. doi: [10.1007/s005860050038](https://doi.org/10.1007/s005860050038). [PubMed: [9629932](https://pubmed.ncbi.nlm.nih.gov/9629932/)]. [PubMed Central: [PMC3611230](https://pubmed.ncbi.nlm.nih.gov/PMC3611230/)].
- Hajivandi S, Dachek A, Salimi A, Mamaghani HJ, Mirghaderi SP, Dehghani J, et al. Comparison of the separate and combined effects of physiotherapy treatment and corticosteroid injection on the range of motion and pain in nontraumatic rotator cuff tear: A randomized controlled trial. *Adv Orthop.* 2021;2021:6789453. doi: [10.1155/2021/6789453](https://doi.org/10.1155/2021/6789453). [PubMed: [34733561](https://pubmed.ncbi.nlm.nih.gov/34733561/)]. [PubMed Central: [PMC8560293](https://pubmed.ncbi.nlm.nih.gov/PMC8560293/)].
- Salimi M, Dehghani J, Gerami MH. Efficacy of elastic

- intramedullary nails in treating axially unstable femur fracture in children. *Pak J Med Health Sci.* 2021;15(1):572-6.
6. Phan D, Bederman SS, Schwarzkopf R. The influence of sagittal spinal deformity on anteversion of the acetabular component in total hip arthroplasty. *Bone Joint J.* 2015;97-B(8):1017-23. doi: [10.1302/0301-620X.97B8.35700](https://doi.org/10.1302/0301-620X.97B8.35700). [PubMed: [26224815](https://pubmed.ncbi.nlm.nih.gov/26224815/)].
 7. Homma Y, Ishii S, Yanagisawa N, Ochi H, Baba T, Nojiri H, et al. Pelvic mobility before and after total hip arthroplasty. *Int Orthop.* 2020;44(11):2267-74. doi: [10.1007/s00264-020-04688-6](https://doi.org/10.1007/s00264-020-04688-6). [PubMed: [32623495](https://pubmed.ncbi.nlm.nih.gov/32623495/)].
 8. Maratt JD, Esposito CI, McLawhorn AS, Jerabek SA, Padgett DE, Mayman DJ. Pelvic tilt in patients undergoing total hip arthroplasty: when does it matter? *J Arthroplasty.* 2015;30(3):387-91. doi: [10.1016/j.arth.2014.10.01](https://doi.org/10.1016/j.arth.2014.10.01). [PubMed: [25453626](https://pubmed.ncbi.nlm.nih.gov/25453626/)]. [PubMed Central: [PMC4359644](https://pubmed.ncbi.nlm.nih.gov/PMC4359644/)].
 9. Wan Z, Malik A, Jaramaz B, Chao L, Dorr LD. Imaging and navigation measurement of acetabular component position in THA. *Clin Orthop Relat Res.* 2009;467(1):32-42. doi: [10.1007/s11999-008-0597-5](https://doi.org/10.1007/s11999-008-0597-5). [PubMed: [18979147](https://pubmed.ncbi.nlm.nih.gov/18979147/)]. [PubMed Central: [PMC2600979](https://pubmed.ncbi.nlm.nih.gov/PMC2600979/)].
 10. Bidaki M, Vosoughi F, Zarei M, Kalantar SH. Diagnosis and management of spinopelvic dissociation. *J Orthop Spine Trauma.* 2021;6(3):61-4. doi: [10.18502/jost.v6i3.4967](https://doi.org/10.18502/jost.v6i3.4967).
 11. Haffer H, Adl AD, Perka C, Pumberger M. The Impact of spinopelvic mobility on arthroplasty: Implications for hip and spine surgeons. *J Clin Med.* 2020;9(8):2569. doi: [10.3390/jcm9082569](https://doi.org/10.3390/jcm9082569). [PubMed: [32784374](https://pubmed.ncbi.nlm.nih.gov/32784374/)]. [PubMed Central: [PMC7464017](https://pubmed.ncbi.nlm.nih.gov/PMC7464017/)].
 12. Fogel GR, Esses SI. Hip spine syndrome: management of coexisting radiculopathy and arthritis of the lower extremity. *Spine J.* 2003;3(3):238-41. doi: [10.1016/s1529-9430\(02\)00453-9](https://doi.org/10.1016/s1529-9430(02)00453-9) [doi]. Retrieved from. [PubMed: [14589205](https://pubmed.ncbi.nlm.nih.gov/14589205/)].
 13. Kurtz S, Ong K, Lau E, Mowat F, Halpern M. Projections of primary and revision hip and knee arthroplasty in the United States from 2005 to 2030. *J Bone Joint Surg Am.* 2007;89(4):780-5. doi: [10.2106/JBJS.F.00222](https://doi.org/10.2106/JBJS.F.00222). [PubMed: [17403800](https://pubmed.ncbi.nlm.nih.gov/17403800/)].
 14. Malkani AL, Garber AT, Ong KL, Dimar JR, Baykal D, Glassman SD, et al. Total hip arthroplasty in patients with previous lumbar fusion surgery: Are there more dislocations and revisions? *J Arthroplasty.* 2018;33(4):1189-93. doi: [10.1016/j.arth.2017.10.041](https://doi.org/10.1016/j.arth.2017.10.041). [PubMed: [29174406](https://pubmed.ncbi.nlm.nih.gov/29174406/)].
 15. Ochi H, Baba T, Homma Y, Matsumoto M, Nojiri H, Kaneko K. Importance of the spinopelvic factors on the pelvic inclination from standing to sitting before total hip arthroplasty. *Eur Spine J.* 2016;25(11):3699-706. doi: [10.1007/s00586-015-4217-2](https://doi.org/10.1007/s00586-015-4217-2). [PubMed: [26329653](https://pubmed.ncbi.nlm.nih.gov/26329653/)].
 16. Sultan AA, Khlopas A, Piuze NS, Chughtai M, Sodhi N, Mont MA. The impact of spino-pelvic alignment on total hip arthroplasty outcomes: A critical analysis of current evidence. *J Arthroplasty.* 2018;33(5):1606-16. doi: [10.1016/j.arth.2017.11.021](https://doi.org/10.1016/j.arth.2017.11.021). [PubMed: [29233568](https://pubmed.ncbi.nlm.nih.gov/29233568/)].
 17. An VVG, Phan K, Sivakumar BS, Mobbs RJ, Bruce WJ. Prior lumbar spinal fusion is associated with an increased risk of dislocation and revision in total hip arthroplasty: A meta-analysis. *J Arthroplasty.* 2018;33(1):297-300. doi: [10.1016/j.arth.2017.08.040](https://doi.org/10.1016/j.arth.2017.08.040). [PubMed: [28974376](https://pubmed.ncbi.nlm.nih.gov/28974376/)].
 18. Endo K, Suzuki H, Nishimura H, Tanaka H, Shishido T, Yamamoto K. Sagittal lumbar and pelvic alignment in the standing and sitting positions. *J Orthop Sci.* 2012;17(6):682-6. doi: [10.1007/s00776-012-0281-1](https://doi.org/10.1007/s00776-012-0281-1). [PubMed: [22915074](https://pubmed.ncbi.nlm.nih.gov/22915074/)].
 19. Boulay C, Tardieu C, Hecquet J, Benaim C, Mouilleseaux B, Marty C, et al. Sagittal alignment of spine and pelvis regulated by pelvic incidence: Standard values and prediction of lordosis. *Eur Spine J.* 2006;15(4):415-22. doi: [10.1007/s00586-005-0984-5](https://doi.org/10.1007/s00586-005-0984-5). [PubMed: [16179995](https://pubmed.ncbi.nlm.nih.gov/16179995/)]. [PubMed Central: [PMC3489325](https://pubmed.ncbi.nlm.nih.gov/PMC3489325/)].
 20. Labelle H, Roussouly P, Berthonnaud E, Transfeldt E, O'Brien M, Chopin D, et al. Spondylolisthesis, pelvic incidence, and spinopelvic balance: A correlation study. *Spine (Phila Pa 1976).* 2004;29(18):2049-54. doi: [10.1097/01.brs.0000138279.53439.cc](https://doi.org/10.1097/01.brs.0000138279.53439.cc). [PubMed: [15371707](https://pubmed.ncbi.nlm.nih.gov/15371707/)].
 21. Luthringer TA, Vigdorich JM. A preoperative workup of a "hip-spine" total hip arthroplasty patient: A simplified approach to a complex problem. *J Arthroplasty.* 2019;34(7S):S57-S70. doi: [10.1016/j.arth.2019.01.012](https://doi.org/10.1016/j.arth.2019.01.012). [PubMed: [30755374](https://pubmed.ncbi.nlm.nih.gov/30755374/)].
 22. Mac-Thiong JM, Labelle H. A proposal for a surgical classification of pediatric lumbosacral spondylolisthesis based on current literature. *Eur Spine J.* 2006;15(10):1425-35. doi: [10.1007/s00586-006-0101-4](https://doi.org/10.1007/s00586-006-0101-4). [PubMed: [16758151](https://pubmed.ncbi.nlm.nih.gov/16758151/)].
 23. Kanawade V, Dorr LD, Wan Z. Predictability of acetabular component angular change with postural shift from standing to sitting position. *J Bone Joint Surg Am.* 2014;96(12):978-86. doi: [10.2106/JBJS.M.00765](https://doi.org/10.2106/JBJS.M.00765). [PubMed: [24951732](https://pubmed.ncbi.nlm.nih.gov/24951732/)].
 24. Ike H, Dorr LD, Trasolini N, Steffl M, McKnight B, Heckmann N. Spine-pelvis-hip relationship in the functioning of a total hip replacement. *J Bone Joint Surg Am.* 2018;100(18):1606-15. doi: [10.2106/JBJS.17.00403](https://doi.org/10.2106/JBJS.17.00403). [PubMed: [30234627](https://pubmed.ncbi.nlm.nih.gov/30234627/)].
 25. Attenello JD, Harpstrite JK. Implications of spinopelvic mobility on total hip arthroplasty: Review of current literature. *Hawaii J Health Soc Welf.* 2019;78(11 Suppl 2):31-40. [PubMed: [31773109](https://pubmed.ncbi.nlm.nih.gov/31773109/)]. [PubMed Central: [PMC6874697](https://pubmed.ncbi.nlm.nih.gov/PMC6874697/)].
 26. Schwab FJ, Blondel B, Bess S, Hostin R, Shaffrey CI, Smith JS, et al. Radiographical spinopelvic parameters and disability in the setting of adult spinal deformity: A prospective multicenter analysis. *Spine (Phila Pa 1976).* 2013;38(13):E803-E812. doi: [10.1097/BRS.0b013e318292b7b9](https://doi.org/10.1097/BRS.0b013e318292b7b9). [PubMed: [23722572](https://pubmed.ncbi.nlm.nih.gov/23722572/)].
 27. Esposito CI, Miller TT, Kim HJ, Barlow BT, Wright TM, Padgett DE, et al. Does degenerative lumbar spine disease influence femoroacetabular flexion in patients undergoing total hip arthroplasty? *Clin Orthop Relat Res.* 2016;474(8):1788-97. doi: [10.1007/s11999-016-4787-2](https://doi.org/10.1007/s11999-016-4787-2). [PubMed: [27020429](https://pubmed.ncbi.nlm.nih.gov/27020429/)]. [PubMed Central: [PMC4925410](https://pubmed.ncbi.nlm.nih.gov/PMC4925410/)].
 28. Zheng GQ, Zhang YG, Chen JY, Wang Y. Decision making regarding spinal osteotomy and total hip replacement for ankylosing spondylitis: experience with 28 patients. *Bone Joint J.* 2014;96-B(3):360-5. doi: [10.1302/0301-620X.96B3.32774](https://doi.org/10.1302/0301-620X.96B3.32774). [PubMed: [24589792](https://pubmed.ncbi.nlm.nih.gov/24589792/)].
 29. Steffl M, Lundergan W, Heckmann N, McKnight B, Ike H, Murgai R, et al. Spinopelvic mobility and acetabular component position for total hip arthroplasty. *Bone Joint J.* 2017;99-B(1 Suppl A):37-45. doi: [10.1302/0301-620X.99B1.BJ-2016-0415.R1](https://doi.org/10.1302/0301-620X.99B1.BJ-2016-0415.R1). [PubMed: [28042117](https://pubmed.ncbi.nlm.nih.gov/28042117/)].