

# Management of Misdiagnosed Bilateral Cervical Facet Dislocation: A Case Report

Yoosef Mehrabi<sup>1</sup>, Christophe Vidal<sup>2</sup>, Saeed Reza Mehrpour<sup>3,\*</sup>, Mohammad Hossein Nabian<sup>4,\*</sup>

<sup>1</sup> Resident, Department of Orthopedic Surgery, Shariati Hospital, School of Medicine, Tehran University of Medical Sciences, Tehran, Iran

<sup>2</sup> Assistant Professor, Department of Pediatric Orthopedics, Robert Debré Hospital, Paris 7 University, AP-HP, Paris, France

<sup>3</sup> Associate Professor, Department of Orthopedic Surgery, Shariati Hospital, School of Medicine, Tehran University of Medical Sciences, Tehran, Iran

<sup>4</sup> Assistant Professor, Department of Orthopedic Surgery, Shariati Hospital, School of Medicine, Tehran University of Medical Sciences, Tehran, Iran

\*Corresponding author: Saeed Reza Mehrpour; Department of Orthopedic Surgery, Shariati Hospital, School of Medicine, Tehran University of Medical Sciences, Tehran, Iran. Tel: +98-9121053939, Email: mehrpour\_saeed@yahoo.com

\*Co-corresponding author: Mohammad Hossein Nabian; Department of Orthopedic Surgery, Shariati Hospital, School of Medicine, Tehran University of Medical Sciences, Tehran, Iran. Tel: +98-9126305095, Email: dr.nabian@gmail.com

Received: 12 November 2021; Revised: 24 December 2021; Accepted: 20 January 2022

## Abstract

**Background:** Despite improvement in technology and decision-making, misdiagnosis or delayed diagnosis of cervical spine injuries in trauma patients can cause severe irreparable neurological damage.

**Case Report:** We present here a 56-year-old man, with a history of old bilateral C4-C5 dislocation who, contrarily to classically described unfavorable results of cranial traction in patients with older than 3 weeks cervical injury, underwent optimal reduction under cranial traction for four days and surgical intervention with an anterior surgical approach.

**Conclusion:** Relatively high incidence of missed cervical spine injuries in polytrauma patients illustrates that proper clinical examination, use of designed protocols for clearance of cervical trauma, and accurate interpretation of radiological imaging can sometimes be neglected.

**Keywords:** Cervical Vertebrae; Fracture Dislocation; Neck Pain; Traction

**Citation:** Mehrabi Y, Vidal C, Mehrpour SR, Nabian MH. Management of Misdiagnosed Bilateral Cervical Facet Dislocation: A Case Report. *J Orthop Spine Trauma* 2022; 8(1): 36-9.

## Background

Increased use of motor vehicles and tendency to heavy and strength sports are commonly responsible for the increase of spinal injuries, which more than 15% of these injuries occur in the cervical spine. Since late diagnosis or failure to diagnose these injuries can cause irreversible damages, careful examination of the cervical spine is essential for early diagnosis and planning for treatment (1). The use of protocols to assess cervical spine injuries along with greater access to accurate imaging devices such as computed tomography (CT) scans and magnetic resonance imaging (MRI) has reduced the delayed diagnosis of cervical spine injuries to about 9.4% (2).

According to Davis et al. (1), the most common reasons for not diagnosing cervical injuries in trauma patients were:

1. Incomplete radiological assessment
2. Misreading of performed imaging
3. Patients with multiple trauma

The most common site of facet dislocation is between the C5-C6 and C6-C7 vertebrae (3). In patients with acute dislocation, the treatment is difficult and involves establishing alignment using external traction and then

anterior +/- posterior fusion (4).

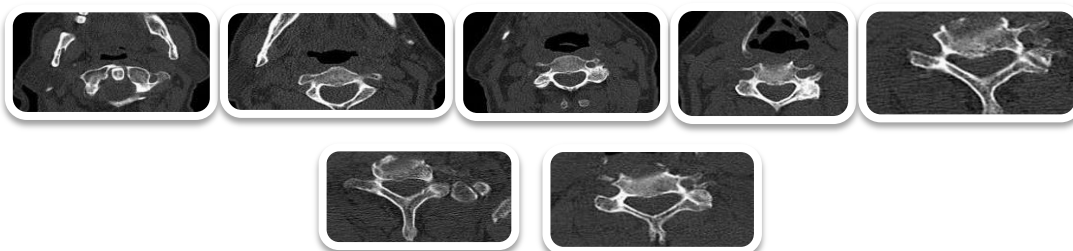
Old injuries, i.e., cases in which diagnosis interval is more than 3 weeks from trauma, are particularly challenging in terms of treatment strategy and previsible results (5).

Studies focusing on the treatment of old bilateral facet fracture dislocation are scarce, especially when diagnosis delay exceeds one month (6).

We introduce a 56-year-old patient with a history of cervical spine trauma occurring about 6 months ago, who was not diagnosed accurately in the initial evaluation. Moreover, the patient did not have proper follow-up due to the coronavirus disease 2019 (COVID-19) pandemic.

## Case Report

A 56-year-old man had referred to the orthopaedic clinic of Shariati Hospital, Tehran, Iran, with a complaint of neck pain 6 months ago. The patient described a fall from a tree; at that time, the patient went to a local medical center and the initial examination and CT scan of the neck were performed and he was discharged with a cervical collar without specific diagnosis. Axial view of cervical spiral CT scan failed to show dislocation (Figure 1).



**Figure 1.** Axial view of cervical spiral computed tomography (CT) scan performed immediately after trauma; degenerative changes and marginal osteophyte formation are seen at C5-C6 and C6-C7 levels



Due to the persistent pain, he referred to another medical center two weeks later and was discharged with a cervical collar and the analgesics after performing cervical MRI. Sagittal view of cervical magnetic resonance imaging (MRI) done 6 weeks after initial trauma showed mild posterolisthesis at C5-C6 (Figure 2). Despite neck pain and weakness of the upper limbs, in the context of COVID-19 pandemic, the patient did not follow up closely and came to our clinic after 6 months of initial trauma.

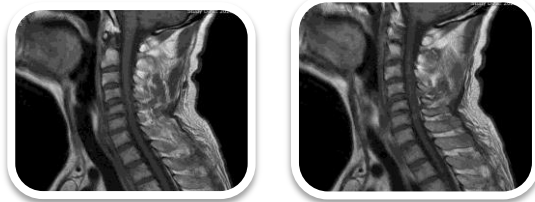


Figure 2. Sagittal view of cervical magnetic resonance imaging (MRI) 6 weeks after initial trauma showing grade 1 C5 posterolisthesis on C6

During his first visit to our spine consultation center, patient's main complaint was isolated prolonged neck pain. Upon clear examination, the patient's cervical lordosis was lost. Mild tenderness on the cervical vertebrae and reduction of upper limb force was found (muscle strange of 4/5). The patient walked independently with a normal gait and the lower extremity neurovascular examination was normal. Cervical anteroposterior (AP) and lateral radiographs were performed. Upon radiography, severe listhesis was seen on C4-C5 vertebrae (Figure 3).

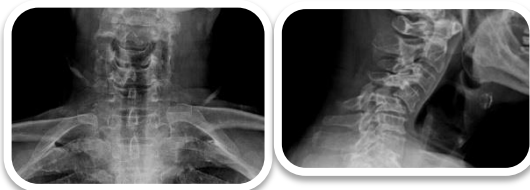

Figure 3. Anteroposterior (AP) and lateral cervical X-ray taken 6 months after trauma, showing severe anterolisthesis of C4 on C5

Therefore, cervical CT scan and MRI were requested for further evaluation (Figures 4 and 5).

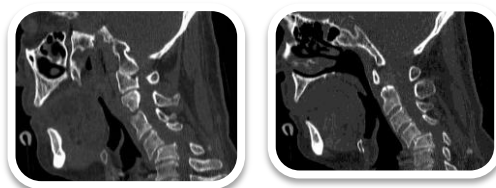


Figure 4. Cervical computed tomography (CT) scan, anterior subluxation of C4 vertebra on C5 with severe narrowing of spinal canal

The patient was admitted immediately and application of cranial traction was decided. Thus, traction started with a 2.5 kg weight. Gradual addition of weight was performed and serial lateral cervical radiographs were taken. Reaching 8 kg, the patient developed paresthesia in the fingers of both hands. Therefore, the weight was reduced to about 6.5 kg and the same amount was maintained until the day of surgery, i.e., 4 days later.

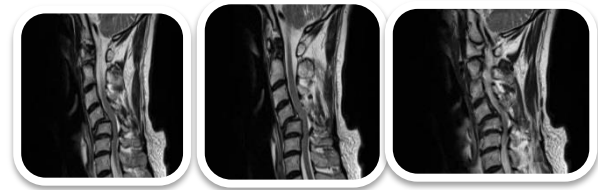

Figure 5. Cervical magnetic resonance imaging (MRI) showing grade 2 anterolisthesis of C4 on C5 with severe central canal stenosis and cervical cord compressive myelopathic change in C4 till C6

In serial radiographies (Figure 6), the listhesis of C4 on C5 was gradually decreased and in a radiography taken just before the start of surgery, the reduction was critical; therefore, surgery was planned with anterior-only approach.

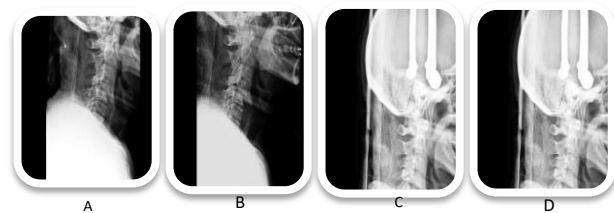


Figure 6. Serial X-ray radiography under cranial traction (A, B, C); C-arm imaging just before surgery (D); cervical spine alignment was corrected under cranial traction

After C4-C5 discectomy and implantation of tricortical bone graft from iliac crest, fixation with anterior fusion plate was performed, under continuous intraoperative neurological monitoring [motor evoked potentials (MEPs) and somatosensory-evoked potentials (SSEPs)] (Figure 7).

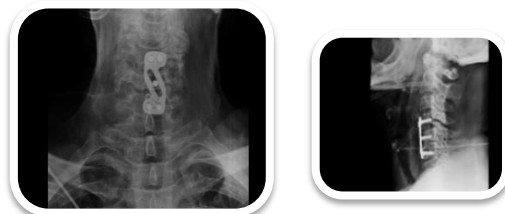

Figure 7. Immediate post-operative X-ray showing anterior C4-C5 fusion

A slight reduction of upper limb force, identical to what was observed before surgery, was noted after surgery. The clinical examination was strictly normal otherwise. The patient was freely mobilized on day 1, discharged with a Philadelphia collar, and advised to keep it for 2 weeks. Three months after surgery in follow-up, the patient's cervical pain had completely improved. He had slight reduction in upper limb forces and clinical examination of the patient's lower limb was all normal (Figure 8).

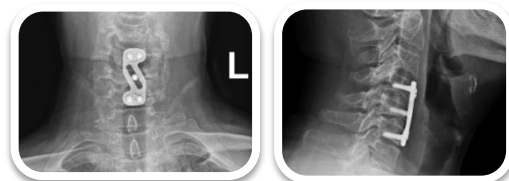

Figure 8. Follow-up X-ray three months after surgery

**Discussion**

Cervical spine injury occurs in 2-3 percent of trauma patients (4). Since late diagnosis and failure to diagnose these injuries may lead to catastrophic results, finding these injuries and planning to begin treatment as soon as possible is critical (7). Misdiagnosis leads to exacerbation of neurological symptoms in 5-10 percent of patients admitted in the emergency room with cervical spine injury (5).

**Clearance of the Cervical Spine in Polytrauma Patient:**

Numerous studies show that in a conscious and not intoxicated patient without neurological symptoms and neck pain, clinical examination for clearing of cervical spine injuries is sufficient (8). At the same time, other studies show that even in conscious patients, clinical examination has a sensitivity of 75-90 percent; therefore, radiological examination is necessary in addition to clinical examination in symptomatic patients. Radiological examinations mostly include X-ray imaging and cervical spine CT scan. Plain radiography has a sensitivity of about 52-80 percent; thus, CT scan with reconstruction with a sensitivity of about 99% gradually replaces plain radiography in the screening of cervical spine injuries in trauma patients (9).

The results of our patient's clinical examination at the time of arrival at the emergency room after initial trauma are not available. As far as we know, the patient underwent a CT scan of the neck, which was not reconstructed in sagittal and coronal planes. As it is difficult to diagnose the listhesis of vertebrae in axial sections, misdiagnosis has occurred. Patient was visited two weeks later and due to his neck pain, cervical MRI was ordered. Mild listhesis as seen on this imaging has been unfortunately neglected and the patient was discharged again with a cervical collar.

**Delayed Diagnosis:**

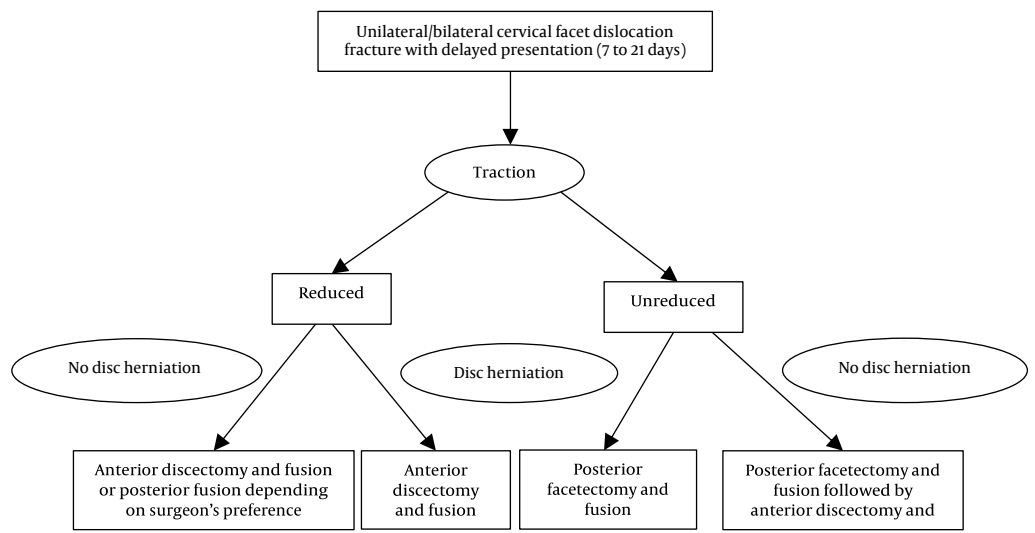
Gerrelts et al. reported delayed diagnosis and failure to diagnose cervical spine injuries in trauma patients at about 8.4% (10). In another study, the most common causes of this lack of diagnosis were: 1) incomplete imaging, 2) incorrect reading of existing imaging, and 3) inadequate examinations, especially in polytrauma patients (1). In the present patient, incomplete reconstruction of performed CT scan and misreading of MRI have been identified as the errors that had occurred.

Therefore, it should be noted that in order to achieve 99% sensitivity of CT scan in the diagnosis of cervical spine injuries, reconstruction in coronal, sagittal, and three-dimensional (3D) views is necessary. Misreading of the MRI leads to recommendation of a systematic validation of a senior radiologist when a junior is in the first line.

**Classification:** Allen et al. described a mechanistic classification for subaxial fracture dislocation of cervical spine. This classification is based on the radiographic patterns of injury and includes 6 stages: 1) compressive flexion, 2) vertical compression, 3) distractive flexion, 4) compressive extension, 5) distractive extension, and 6) lateral flexion injuries. Facet fracture-dislocations of stage 3-4 are distractive flexion injuries that are severely unstable injuries (11).

**Management of Cervical Spine Facet Dislocation:** In acute cases, they are initially treated with cranial traction. If treatment is unsuccessful, open reduction is performed with an anterior or posterior approach or both (12). Dislocation is considered old when more than three weeks have passed since the initial injury (13). In these cases, fibrous formation around the fascia and vertebrae with remodeling makes it difficult to reduce joint articular surfaces (5). In a study, Hassan used cranial traction to treat 12 old dislocations, with only 2 cases of optimal reduction obtained (14).

In another study, Jain et al. did not use this method in other cases to treat 4 cases of old dislocation due to the failure of closed reduction with traction in the first used therapy. The success rate of closed reduction with traction in dislocations after more than 72 hours is about 20% (5). It is recommended to perform cervical MRI before traction, because it is assumed that applying traction can compress the cord by transferring the extruded disc to the canal, or the edematous and swollen cord may be damaged. In another article, Basu et al. treated 14 patients with unilateral facet dislocation by closed reduction with cranial traction. Depending on the success of closed reduction, in successful cases (10/14), anterior discectomy and fusion were performed. In cases where closed reduction was not successful, the posterior facetectomy, reduction, and fusion were performed. Five patients with bilateral dislocation underwent posterior facetectomy, lateral mass fixation, and anterior fusion surgery (15) (Figure 9).



**Figure 9.** Algorithm for old cervical facet dislocation



As mentioned before, Hassan treated 12 patients with old bilateral dislocation with closed reduction via traction. In patients with successful reduction, plate fixation was accomplished only from the anterior approach. In cases where the reduction was not successful, the posterior open reduction was performed. In successful cases, fixation was performed with lateral mass screw. In case of failure with posterior release, the traction was kept for another week and then anterior discectomy and fusion were performed (14).

In our patient, it was decided to implant cranial traction and evaluate the patient's response with serial lateral cervical radiography. The traction result was better than expected. Despite the impossibility of increasing the weight over than 6.5 kg due to the neurological symptoms in patient, after 4 days of traction and on the verge of surgery, the reduction reached a very good level. In such a way, the patient's need for surgery was met. Therefore, after transferring the patient to operating room (OR), the weights were reduced by half. The patient with anterior approach first underwent discectomy. The tricortical bone graft was implanted in the disc space. Then with an anterior fusion plate, fusion was accomplished. Philadelphia collar was implanted for the patient. After surgery, the patient was in good condition. In the first follow-up two weeks after surgery, patient's neck pain greatly improved, but the weakness of the upper limbs still remained. Three months after surgery, the patient's neck pain was relieved and weakness of the upper limbs showed a slight improvement.

### Conclusion

Every effort should be made to properly diagnose cervical injuries in a timely manner. The availability of advanced imaging equipment has not eliminated the risk of misdiagnosis of cervical spine injuries. Therefore, special attention should be paid to the importance of clinical examination in order to obtain diagnostic keys and achieve maximum efficiency of different imaging modalities through senior physician training. If, despite all efforts, the physicians meet an old dislocation, the choice of treatment should be based on the patient's response to the installation of the cranial traction. If successful (including in old dislocations), a very traumatic posterior surgery is avoided as a first step and anterior-only approach for discectomy and fusion is selected. For cases with unsuccessful closed reduction, posterior approach for facetectomy and fusion followed by anterior approach is a surgical strategy.

### Conflict of Interest

The authors declare no conflict of interest in this study.

### Acknowledgements

We would like to show our gratitude to Christophe Vidal (Assistant Professor, Department of Pediatric Orthopedics, Robert Debré Hospital, Paris, France) for sharing his pearls of wisdom with us during the course of this research.

### References

- Davis JW, Phreaner DL, Hoyt DB, Mackersie RC. The etiology of missed cervical spine injuries. *J Trauma*. 1993;34(3):342-6. doi: [10.1097/00005373-199303000-00006](https://doi.org/10.1097/00005373-199303000-00006). [PubMed: 8483172].
- Karamian BA, Schroeder GD, Holas M, Joaquim AF, Canseco JA, Rajasekaran S, et al. Variation in global treatment for subaxial cervical spine isolated unilateral facet fractures. *Eur Spine J*. 2021;30(6):1635-50. doi: [10.1007/s00586-021-06818-z](https://doi.org/10.1007/s00586-021-06818-z). [PubMed: 33797624].
- Anissipour AK, Agel J, Bellabarba C, Bransford RJ. Cervical facet dislocations in the adolescent population: A report of 21 cases at a level 1 trauma center from 2004 to 2014. *Eur Spine J*. 2017;26(4):1266-71. doi: [10.1007/s00586-017-5003-0](https://doi.org/10.1007/s00586-017-5003-0). [PubMed: 28247075].
- Koivikko MP, Myllynen P, Santavirta S. Fracture dislocations of the cervical spine: A review of 106 conservatively and operatively treated patients. *Eur Spine J*. 2004;13(7):610-6. doi: [10.1007/s00586-004-0688-2](https://doi.org/10.1007/s00586-004-0688-2). [PubMed: 15300472]. [PubMed Central: PMC3476653].
- Jain AK, Dhammi IK, Singh AP, Mishra P. Neglected traumatic dislocation of the subaxial cervical spine. *J Bone Joint Surg Br*. 2010;92(2):246-9. doi: [10.1302/0301-620X.92B2.22963](https://doi.org/10.1302/0301-620X.92B2.22963). [PubMed: 20130317].
- Gao W, Wang B, Hao D, Zhu Z, Guo H, Li H, et al. Surgical treatment of lower cervical fracture-dislocation with spinal cord injuries by anterior approach: 5- to 15-year follow-up. *World Neurosurg*. 2018;115:e137-e145. doi: [10.1016/j.wneu.2018.03.213](https://doi.org/10.1016/j.wneu.2018.03.213). [PubMed: 29631085].
- Nagata K, Inokuchi K, Chikuda H, Ishii K, Kobayashi A, Kanai H, et al. Early versus delayed reduction of cervical spine dislocation with complete motor paralysis: A multicenter study. *Eur Spine J*. 2017;26(4):1272-6. doi: [10.1007/s00586-017-5004-z](https://doi.org/10.1007/s00586-017-5004-z). [PubMed: 28247074].
- Sanchez B, Waxman K, Jones T, Conner S, Chung R, Becerra S. Cervical spine clearance in blunt trauma: Evaluation of a computed tomography-based protocol. *J Trauma*. 2005;59(1):179-83. doi: [10.1097/01.ta.0000171449.94650.8i](https://doi.org/10.1097/01.ta.0000171449.94650.8i). [PubMed: 16096560].
- Larson S, Delnat AU, Moore J. The Use of clinical cervical spine clearance in trauma patients: A literature review. *J Emerg Nurs*. 2018;44(4):368-74. doi: [10.1016/j.jen.2017.10.013](https://doi.org/10.1016/j.jen.2017.10.013). [PubMed: 29203049].
- Gerrelts BD, Petersen EU, Mabry J, Petersen SR. Delayed diagnosis of cervical spine injuries. *J Trauma*. 1991;31(12):1622-6. doi: [10.1097/00005373-199112000-00010](https://doi.org/10.1097/00005373-199112000-00010). [PubMed: 1749033].
- Allen BL, Ferguson RL, Lehmann TR, O'Brien RP. A mechanistic classification of closed, indirect fractures and dislocations of the lower cervical spine. *Spine (Phila Pa 1976)*. 1982;7(1):1-27. doi: [10.1097/00007632-198200710-00001](https://doi.org/10.1097/00007632-198200710-00001). [PubMed: 7071658].
- Loughenbury P. Cervical spine fracture-dislocation. In: Giannoudis PV, editor. *Fracture reduction and fixation techniques*. New York, NY: Springer; 2020. p. 1-13.
- Kanna RM, Shetty AP, Rajasekaran S. Modified anterior-only reduction and fixation for traumatic cervical facet dislocation (AO type C injuries). *Eur Spine J*. 2018;27(6):1447-53. doi: [10.1007/s00586-017-5430-y](https://doi.org/10.1007/s00586-017-5430-y). [PubMed: 29279998].
- Hassan MG. Treatment of old dislocations of the lower cervical spine. *Int Orthop*. 2002;26(5):263-7. doi: [10.1007/s00264-002-0350-8](https://doi.org/10.1007/s00264-002-0350-8). [PubMed: 12378349]. [PubMed Central: PMC3620986].
- Basu S, Malik FH, Ghosh JD, Tikoo A. Delayed presentation of cervical facet dislocations. *J Orthop Surg (Hong Kong)*. 2011;19(3):331-5. doi: [10.1177/230949901101900314](https://doi.org/10.1177/230949901101900314). [PubMed: 22184165].