

# The Role of Medial Buttress Plate Augmentation of Cannulated Screws in Unstable Femoral Neck Fractures: A Pilot Study

Sayyed Hadi Sayyed Hoseinian<sup>1</sup>, Ali Birjandi Nejad<sup>2</sup>, Farshid Bagheri<sup>1</sup>, Mohammad Taghi Peivandi<sup>3</sup>, Ehsan Vahedi<sup>2</sup>, Amin Razi<sup>3</sup>, Ghasem Zamani<sup>1,2,\*</sup>, Ali Parsa<sup>2</sup>

<sup>1</sup> Assistant Professor, Department of Orthopedic Surgery, Shahid Kamyab Hospital, School of Medicine, Mashhad University of Medical Sciences, Mashhad, Iran

<sup>2</sup> Associate Professor, Department of Orthopedic Surgery, Shahid Kamyab Hospital, School of Medicine, Mashhad University of Medical Sciences, Mashhad, Iran

<sup>3</sup> Specialist in Orthopedic Surgery, Department of Orthopedic Surgery, Shahid Kamyab Hospital, School of Medicine, Mashhad University of Medical Sciences, Mashhad, Iran

\*Corresponding author: Ghasem Zamani; Department of Orthopedic Surgery, Shahid Kamyab Hospital, School of Medicine, Mashhad University of Medical Sciences, Mashhad, Iran. Tel: +98-9378071868, Email: ghasem.zamani92@gmail.com

Received: 05 October 2020; Revised: 22 December 2020; Accepted: 09 February 2021

## Abstract

**Background:** About 20% of femoral neck fracture surgeries require re-operation. The use of medial buttress plate may reduce the re-operation rate. The purpose of this study is to examine the results of using the method of augmentation of the cannulated screws with medial buttress plate for treatment of unstable femoral neck fractures.

**Methods:** This study included patients with femoral neck fractures of Pauwels type 2 and 3 in which closed reduction was not successful. The patients underwent open anatomical reduction and implantation of three screws, and then the medial placement of the buttress plate was performed. Patients were followed up after 2 weeks, 6 weeks, 3 months, and 6 months. Union and fracture healing and operative complications were assessed using plain radiography.

**Results:** This study included 8 patients with Pauwels type 2 and 3 femoral neck fractures. All patients were men with the mean age of  $38.0 \pm 11.3$  years. Re-hospitalization 30 days after surgery, surgical site infection, deep vein thrombosis (DVT), and deep infection were not observed in any of the patients. The angle between the neck and the femur shaft dramatically increased during the 6-month follow-up ( $P = 0.049$ ). Union occurred in 6 (75%) patients after 6 months, while 2 patients were lost to follow up. Participants' Harris Hip Score (HHS) had a significant improvement from 3 months to 6 months after surgery ( $P = 0.02$ ).

**Conclusion:** Augmentation of cannulated screws with medial buttress plate for unstable femoral neck fractures in patients has advantages in short-term clinical follow-up.

**Keywords:** Bone Plates; Bone Screws; Femoral Neck Fractures; Fracture Fixation; Surgical Fixation Devices

**Citation:** Sayyed Hoseinian SH, Birjandi Nejad A, Bagheri F, Peivandi MT, Vahedi E, Razi A, et al. **The Role of Medial Buttress Plate Augmentation of Cannulated Screws in Unstable Femoral Neck Fractures: A Pilot Study.** *J Orthop Spine Trauma* 2021; 7(1): 12-6.

## Background

Femoral neck fractures in young adults are commonly caused by high-energy traumas (1). These injuries can be associated with vertical fractures, which cause a high shear load at the fracture site and increase the likelihood of internal fixation failure (2). Recently, a meta-analysis showed that the rate of reoperation was 18% in femoral neck fractures, 9% in non-union, 14% in avascular necrosis (AVN), and 10% in implant defects (3). Currently, there is no gold standard for the treatment of Pauwels type II and III fractures. Pauwels type III and type II fractures are recognized as the most vertical fractures, respectively. Fixation of these fractures with the common method, which is the use of three cannulated screws, is associated with non-union in 16-59 percent of cases and osteonecrosis in 11-86 percent of cases (2, 4). Therefore, it is necessary to change the operation technique in these cases to increase the stability and rigidity of fixation.

The use of a plate in the medial part of the femoral neck in combination with screws has been proposed in recent studies to improve fixation stability. Few studies in this area have reported satisfactory results, and the union rate has been reported to be as high as 89 percent with less complications (5-7). In Iran, due to the high number of accidents and high-energy traumas, the prevalence of this type of fracture is high. To improve fixation stability, Mir

and Collinge suggested the use of a medial buttress plate for vertical femoral neck fractures (8). Although limited studies have examined the primary results of this operation, the use of a medial buttress plate may increase the success of the surgery by improving the fixation stability. In this pilot study, we attempted to evaluate the effectiveness of this method.

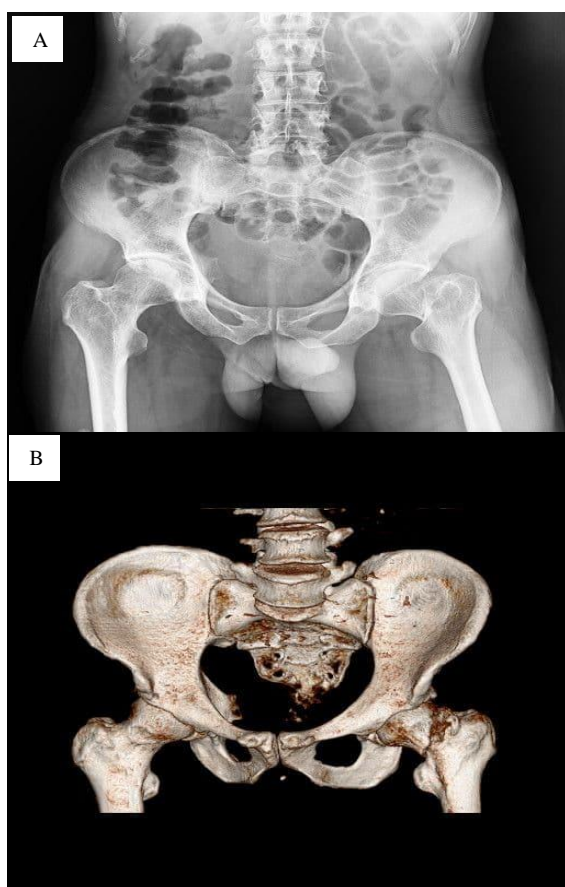
## Methods

**Study Design:** This interventional single-arm clinical trial was conducted among patients with Pauwels type II and III femoral neck fractures, who underwent surgery in the orthopedic wards of Imam Reza Hospital and Emdadi Hospital, Mashhad, Iran, between 2018 and 2020. The subjects were selected via available sampling. The inclusion criteria were as follows: 1) age range of 18-60 years, 2) Pauwels type II and III femoral neck fractures, and 3) failed closed reduction. The exclusion criteria were as follows: 1) open fractures, 2) uncontrolled underlying diseases [e.g., diabetes mellitus (DM), rheumatic diseases, immunodeficiency, and cancer], 3) successful closed reduction, 4) concomitant acetabular and pelvic ring fractures on the same side, 5) concomitant hip dislocation on the same side, 6) use of immunosuppressive drugs, and 7) lack of patient consent or cooperation. After reviewing the possible alternatives



and explanation of the study procedures, written consent was taken from all participants. This research was acknowledged by the Ethics Committee of Mashhad University of Medical Sciences (No. IR.MUMS.MEDICAL.REC.1399.398).

**Surgical Procedures:** In all patients, open reduction was performed through the anterior approach (Smith-Peterson) after two unsuccessful attempts at closed reduction. The fracture site was exposed while maintaining the blood flow. Then, the reduction was restored, and fixation was performed according to the standard method with three 6.5 mm cannulated screws under a scope guide. Next, the foot was rotated externally as far as possible, and a 1.3 mm tubular plate was inserted into the medial part (at 5 o'clock). Depending on the fracture site, we used one or two proximal screws and two or three distal screws (Figures 1 and 2).

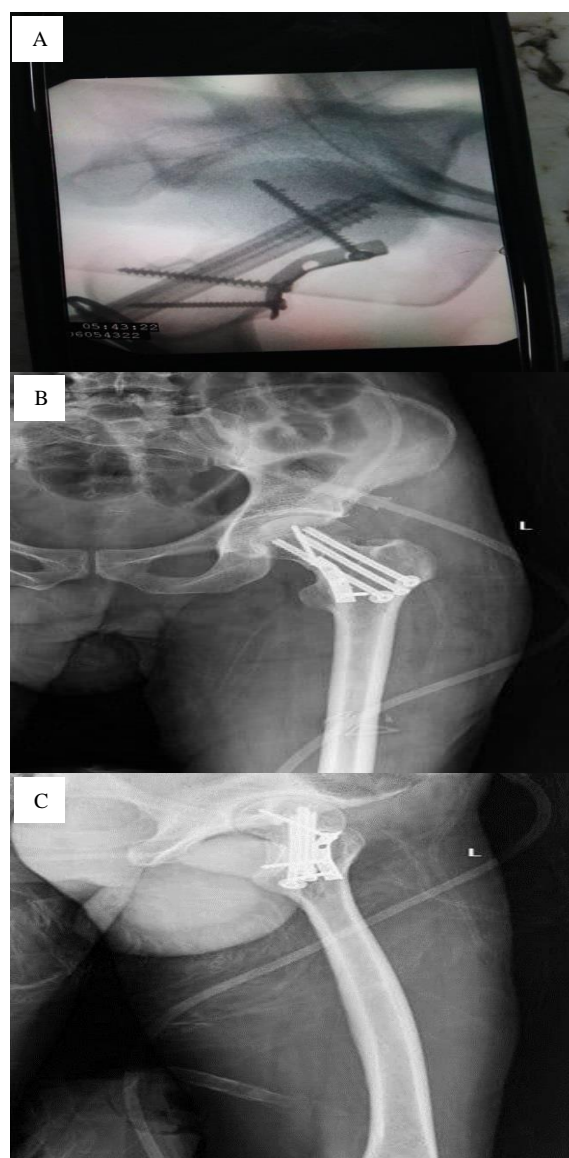


**Figure 1:** A: Preoperative anteroposterior (AP) X-ray of pelvis (femoral neck fracture); B: Three-dimensional (3D) computed tomography (CT) scan (preoperative)

**Follow-up and Assessment:** The follow-up of patients was performed at intervals of two weeks, six weeks, three months, and six months. During the follow-up visits, radiographs of the anterior and lateral aspects of the hip were obtained to evaluate the bone union and possible complications, including osteonecrosis and device failure. We also assessed the status of surgical wound healing and possible infection. Harris Hip Score (HHS) and Merle d'Aubigné hip score were used to evaluate the hip joint function. HHS ranges between 0 to 100 with higher score showing the better outcome. The Merle d'Aubigné hip score includes the parameters of pain, mobility, and ability to walk, with each rating from 0 points (worst condition) to 6 points (best condition). The

femoral neck-shaft angle (NSA), the angle formed by femoral shaft axis and femoral neck, was measured to evaluate the biomechanics of the hip joint before and after the surgery. The Garden classification was used to evaluate the displacement of femoral neck fractures. The tool classifies femoral neck fracture into 4 subgroups: an incomplete femoral neck fracture with valgus impaction is considered as grade I; a complete fracture without displacement is considered as grade II; grade III fracture is a complete and partially-displaced fracture; and grade IV is a complete fracture with full displacement.

**Statistical Analysis:** Categorical and continuous variables were presented as frequency (%) and mean  $\pm$  standard deviation (SD), respectively. To compare the continuous measures before and after the surgery, paired samples t-test was used. Friedman test was used to test for significant differences during the course of follow-up. Data were analyzed using SPSS software (version 16, SPSS Inc., Chicago, IL, USA). P-values of less than 0.05 were considered statistically significant.



**Figure 2:** A: Intraoperative fluoroscopy of buttress plate placement over screw fixation; B: Post-operative control anteroposterior (AP) X-ray; C: Lateral postoperative X-ray

## Results

A total number of 8 patients were finally included, all of which were men with a mean age of  $38.0 \pm 11.3$  years (range: 18-58 years). The mean body mass index (BMI) of the patients was  $24.1 \pm 4.6$  kg/m<sup>2</sup>. The level of education in most patients was below high school diploma (n = 6, 0.75%). The right and left legs were affected in 3 (37.5%) and 5 (62.5%) patients, respectively. No contralateral fracture was seen in any of the patients. In all patients, the femoral neck fracture was caused by high-energy trauma and was grade III according to the Garden classification. Similarly, most fractures were type III according to the Pauwels classification (n = 7, 87.5%) (Table 1).

Features	Patient group (n = 8)
<b>Involved leg [n (%)]</b>	
Right	3 (37.5)
Left	5 (62.5)
<b>Type of fracture according to Pauwels criteria [n (%)]</b>	
II	1 (12.5)
III	7 (87.5)
<b>Lateral ipsilateral fracture [n (%)]</b>	
Yes	3 (37.5)
No	5 (62.5)
<b>Interval between the incidence of fracture and transfer to the operating room (hour)*</b>	49 (25-194)

Median (first quartile-third quartile) was measured to represent the distribution of this variable

The mean duration of surgery was  $2.0 \pm 0.8$  hours. Admission to the intensive care unit (ICU) was reported in only one patient (12.5%) who had 500 cc of bleeding and required packed cells. We did not observe complications such as thirty-day readmission after the surgery, surgical site infection, deep vein thrombosis (DVT), deep infection, AVN, or lateral femoral cutaneous nerve (LFCN) damage in any of the patients. According to the Tönnis classification for osteoarthritis (OA) of the hip, none of the patients had arthritic changes at the beginning of the study. However, at the end of the study, three patients were Tönnis grade 1 (37.5%), indicating the presence of osteophyte in these patients. Table 2 provides more information regarding the intraoperative and postoperative variables.

Variables	Patient group (n = 8)
Duration of surgery (hour)	$2.0 \pm 0.8$
Duration of anesthesia (hour)	$3.1 \pm 0.8$
Postoperative admission to the ICU	1 (12.5)
Hospitalization duration (day)	$4.5 \pm 1.5$
Thirty-day readmission after surgery	0 (0)
Infection at the surgical site	0 (0)
DVT	0 (0)
Deep infection	0 (0)
Reduction in the lower calcar portion at the beginning of the study	2 (25.0)
Reduction in the lower calcar portion at the end of the study	2 (25.0)
Non-union rate at the end of the study	0 (0)
Mild pain at the end of the study	8 (100)
AVN	0 (0)
Implant failure	2 (33.3)
Impingement syndrome	1 (16.5)
Damage to the external subcutaneous nerve of the thigh	0 (0)
Incision size at the surgical site (cm)	$10.8 \pm 2.3$
Observation of osteophyte based on Tönnis system at the beginning of the study	0 (0)
Observation of osteophyte based on Tönnis system at the end of the study	3 (37.5)

Data are presented as mean  $\pm$  standard deviation (SD) or number and percentage  
 ICU: Intensive care unit; DVT: Deep vein thrombosis; AVN: Avascular necrosis

At the end of the six-month follow-up, union was

achieved in six out of eight patients. Of the two patients with nonunion, one underwent hemiarthroplasty three months after the first surgery in another center, and the other underwent screw replacement surgery with a dynamic hip screw (DHS) in another center four months after the first surgery. These two patients did not complete the follow-up.

The mean NSA changed significantly from  $134.0 \pm 10.3$  degrees before the surgery to  $135.7 \pm 4.1$  degrees at six-month follow-up (P = 0.049, Friedman test). The HHS significantly improved from the mean score of  $70.3 \pm 16.4$  at three months after the surgery to  $84.0 \pm 10.4$  at six months after the surgery (P = 0.02, paired t-test). However, evaluation of the patients with Merle d'Aubigné hip scoring system did not show any significant improvement in patients from three to six months after the surgery (P = 0.14). Table 3 represents a summary of hip scores.

Variables	Patient group (n = 8)	P-value
NSA at the beginning of the study	$134.0 \pm 10.3$	
NSA at three months after the study	$135.7 \pm 4.1$	0.049
NSA at six months after the study	$135.7 \pm 4.1$	
Harris score at three months after the study	$70.3 \pm 16.4$	0.020
Harris score at six months after the study	$84.0 \pm 10.4$	
Merle d'Aubigné hip score at three months after the study	$32.3 \pm 6.4$	
Merle d'Aubigné hip score at six months after the study	$35.8 \pm 4.7$	0.140

NSA: Neck-shaft angle

## Discussion

For the treatment of Pauwels type II and III femoral neck fractures, there is currently no gold standard. The use of a plate in combination with screws in the medial part of the femoral neck has been suggested by recent researches to increase fixation stability. Limited studies have indicated the favorable outcomes of this approach, and the rate of union has been reported to be as high as 89% with fewer complications (7, 8). In this study, eight patients with Pauwels type II and III femoral neck fractures underwent open reduction surgery, cannula implantation, and placement of medial buttress plate using the anterior approach. Although this method of treatment has significantly increased the NSA and HHS in our patients, it has failed to show any significant improvement in the Merle d'Aubigné hip score.

Whether or not the treatment procedure damages the blood flow to the femoral head is one of the crucial concerns regarding femoral neck fractures. A classic research by Gautier et al. confirmed that primary blood supply to the femoral head was provided by the deep branch of the medial femoral circumflex artery (MFCA) (9). Anterior direct access to the hip bone has been accepted as a neuromuscular maintenance approach. The lateral femoral circumflex artery (LFCA) which only provides limited blood supply to the femoral head, is the only damaged structure in this procedure. Also, open surgery can drain the intracapsular hematoma, which may contribute to high joint pressure and cause AVN of the femoral head (10).

Other studies have been conducted in this area, including a study by Schwartzmann et al., which investigated the effect of DHS in the treatment of femoral neck fractures with displacement and osteonecrosis in young patients (11). A total of 53 patients under 55 years of age were retrospectively evaluated in their study. All

patients had femoral neck fractures with displacement (Garden type III or IV) and were treated with DHS. The Ficat staging system was used to evaluate AVN. The study population included 38 men and 15 women with the mean age of  $14.9 \pm 12.8$  years. 21 fractures were known as type III, while 32 fractures were classified in type IV group, based on the Garden system. Although fracture treatment was successfully achieved in 39 patients, 13 cases developed AVN. Overall, the incidence of AVN was estimated at 24.6% in young patients with femoral neck fractures and displacement who were treated with DHS. There was no significant relationship between osteonecrosis and the time elapsed until surgery or fracture displacement. The higher rate of AVN in their study may be due to the larger sample size, compared to our results.

Ye et al. evaluated the complications of femoral neck fractures (Pauwels type III) treated with three cannulated screws and medial buttress plates (7). Through the anterior approach, 28 patients below the age of 60 years with femoral neck fractures (Pauwels type III) were treated by open reduction and internal fixation. The fractures were treated with three cannulated screws, augmented with a medial buttress plate. In all patients, all reductions achieved Garden's alignment index grade one. According to them, fracture union without shortening was achieved in 89% of the patients. Implant failure occurred in three patients with shortening of the femoral neck. However, AVN did not occur in any of the patients during 13.6-month follow-up. The researchers concluded that treating femoral neck fractures (Pauwels type III) using cannulated screws augmented with a medial buttress plate significantly increased the success of fracture union compared to cannula plates alone. In addition, the use of medial plates did not increase the risk of complications, including AVN. They demonstrated that plate thickness could reduce the stimulation of internal structures of the femoral neck and effectively support the fracture. In combined treatments, the function of the plate is to resist the vertical shear and protect the structure of the cannulated screw against failure before fracture union. Generally, cannulated screws are still the most critical element of fixation. Iatrogenic impingement can be prevented by proper plate placement during surgery. It should be noted that the buttress plate should not be placed too high or too far forward from the femoral neck (7); the results of this study are in line with the current research.

Kunapuli et al. compared the strength of augmented versus non-augmented techniques for stabilizing femoral neck fractures. They evaluated two methods of augmented cannulated screws with a plate and DHS: 1) 7.3 mm cannulated screws in an inverted triangle shape, and 2) 135-degree DHS. Augmentation consisted of a 2.7-mm locking plate located on the anterior-inferior surface of the femoral neck. Overall, cannulated screws were 26% less likely to fail compared to DHS ( $P < 0.01$ ). Finally, it was reported that fixation of fractures with cannulated screws was significantly stronger than DHS, which is in accordance with the results of our study. It should be noted that successful treatment of Pauwels type III fractures requires fixation to resist vertical shearing and maintain bone reduction and fixation stability during the healing process, without damaging the femoral head blood flow. They also concluded that fixation with augmented techniques using medial buttress plates was significantly less likely to fail in vertical femoral neck fractures (12).

This study has several limitations: first, the

coronavirus disease 2019 (COVID-19) pandemic that imposed certain limitations on the study procedures, including the collection of required sample volume; second, the small number of patients who met the inclusion criteria; third, the long follow-up period and lack of patients' cooperation; and finally, the absence of a control group and evaluation of patient-related factors, that makes it difficult to draw conclusions about the effects of this new technique or compare it with the traditional ones.

### Conclusion

Results of our pilot study and the available evidence support the performance of plate augmentation to reduce treatment failures, but existing evidence is heterogeneous and the quality of evidence is low.

### Conflict of Interest

The authors declare no conflict of interest in this study.

### Acknowledgements

None.

### References

1. Robinson CM, Court-Brown CM, McQueen MM, Christie J. Hip fractures in adults younger than 50 years of age. Epidemiology and results. *Clin Orthop Relat Res.* 1995;(312):238-46. [PubMed: 7634609].
2. Liporace F, Gaines R, Collinge C, Haidukewych GJ. Results of internal fixation of Pauwels type-3 vertical femoral neck fractures. *J Bone Joint Surg Am.* 2008;90(8):1654-9. doi: 10.2106/JBJS.G.01353. [PubMed: 18676894].
3. Damany DS, Parker MJ, Chojnowski A. Complications after intracapsular hip fractures in young adults. A meta-analysis of 18 published studies involving 564 fractures. *Injury.* 2005;36(1):131-41. doi: 10.1016/j.injury.2004.05.023. [PubMed: 15589931].
4. Grisoni N, Foulk D, Spratt D, Laughlin RT. Simultaneous bilateral hip fractures in a level I trauma center. *J Trauma.* 2008;65(1):132-5. doi: 10.1097/TA.0b013e318060d29a. [PubMed: 18580534].
5. Xiong WF, Chang SM, Zhang YQ, Hu SJ, Du SC. Inferior calcar buttress reduction pattern for displaced femoral neck fractures in young adults: A preliminary report and an effective alternative. *J Orthop Surg Res.* 2019;14(1):70. doi: 10.1186/s13018-019-1109-x. [PubMed: 30819226]. [PubMed Central: PMC6396447].
6. Guimaraes JAM, Rocha LR, Noronha Rocha TH, Bonfim DC, da Costa RS, Dos Santos CA, et al. Vertical femoral neck fractures in young adults: A closed fixation strategy using a transverse cancellous lag screw. *Injury.* 2017;48(Suppl 4):S10-S16. doi: 10.1016/S0020-1383(17)30769-6. [PubMed: 29145961].
7. Ye Y, Chen K, Tian K, Li W, Mauffrey C, Hak DJ. Medial buttress plate augmentation of cannulated screw fixation in vertically unstable femoral neck fractures: Surgical technique and preliminary results. *Injury.* 2017;48(10):2189-93. doi: 10.1016/j.injury.2017.08.017. [PubMed: 28818323].
8. Mir H, Collinge C. Application of a medial buttress plate may prevent many treatment failures seen after fixation of vertical femoral neck fractures in young adults. *Med Hypotheses.* 2015;84(5):429-33. doi: 10.1016/j.mehy.2015.01.029. [PubMed: 25744726].
9. Gautier E, Ganz K, Krugel N, Gill T, Ganz R. Anatomy of the

- medial femoral circumflex artery and its surgical implications. *J Bone Joint Surg Br.* 2000;82(5):679-83. doi: [10.1302/0301-620X.82B5.10426](https://doi.org/10.1302/0301-620X.82B5.10426). [PubMed: [10963165](https://pubmed.ncbi.nlm.nih.gov/10963165/)].
10. Swiontkowski MF, Winquist RA, Hansen ST Jr. Fractures of the femoral neck in patients between the ages of twelve and forty-nine years. *J Bone Joint Surg Am.* 1984;66(6):837-46. doi: [10.2106/00004623-198466060-00003](https://doi.org/10.2106/00004623-198466060-00003). [PubMed: [6736085](https://pubmed.ncbi.nlm.nih.gov/6736085/)].
  11. Schwartzmann CR, Lammerhirt HM, Spinelli LF, Ungaretti Neto ADS. Treatment of displaced femoral neck fractures in young patients with DHS and its association to osteonecrosis. *Rev Bras Ortop.* 2018;53(1):82-7. doi: [10.1016/j.rboe.2017.03.003](https://doi.org/10.1016/j.rboe.2017.03.003). [PubMed: [29367911](https://pubmed.ncbi.nlm.nih.gov/29367911/)]. [PubMed Central: [PMC5771783](https://pubmed.ncbi.nlm.nih.gov/PMC5771783/)].
  12. Kunapuli SC, Schramski MJ, Lee AS, Popovich JM Jr, Cholewicki J, Reeves NP, et al. Biomechanical analysis of augmented plate fixation for the treatment of vertical shear femoral neck fractures. *J Orthop Trauma.* 2015;29(3):144-50. doi: [10.1097/BOT.0000000000000205](https://doi.org/10.1097/BOT.0000000000000205). [PubMed: [25072287](https://pubmed.ncbi.nlm.nih.gov/25072287/)].