

A Case Report of Simultaneous Ipsilateral Floating Knee and Hip

Babak Siavashi¹, Seyyed Hossein Shafiei^{1,2,*}, Farhad Mahdavi³, Salar Baghbani³, Mohammad Reza Golbakhsh¹

¹ Associate Professor, Department of Orthopedic Surgery, Sina Hospital, School of Medicine, Tehran University of Medical Sciences, Tehran, Iran

² Assistant Professor, Department of Orthopedic Surgery, Sina Hospital, School of Medicine, Tehran University of Medical Sciences, Tehran, Iran

³ Resident, Department of Orthopedic Surgery, Sina Hospital, School of Medicine, Tehran University of Medical Sciences, Tehran, Iran

*Corresponding author: Seyyed Hossein Shafiei; Department of Orthopedic Surgery, Sina Hospital, School of Medicine, Tehran University of Medical Sciences, Tehran, Iran. Tel: +98-2163121297, Email: dr_hshafiei@yahoo.com

Received: 03 April 2020; Revised: 20 June 2020; Accepted: 11 August 2020

Abstract

Background: Simultaneous ipsilateral floating knee and hip is a very rare injury and so far, no standard guideline has been determined for its treatment.

Case Report: In the current study, we report a surgical technique for the treatment of a 17-year-old patient with this condition on his left side.

Conclusion: We recommend to start the fixation from proximal and stabilize the pelvic ring at first, then fix the posterior part of the acetabulum and femoral shaft with the same posterior approach.

Keywords: Hip Injuries; Knee Injuries; Acetabulum

Citation: Siavashi B, Shafiei SH, Mahdavi F, Baghbani S, Golbakhsh MR. A Case Report of Simultaneous Ipsilateral Floating Knee and Hip. *J Orthop Spine Trauma* 2020; 6(3): 72-4.

Background

The coincidence of ipsilateral floating hip (fracture of the pelvis/acetabulum and femur) and floating knee (fracture of the femoral and tibial shaft) is a rare condition with only a few reports in the literature (1, 2). While the mortality and morbidity rates are high, the best order of fixation is not yet defined and management of such injuries can be extremely demanding (3, 4).

In this study, we report a surgical technique for the treatment of simultaneous ipsilateral floating hip and knee.

Case Report

A 17-year-old man referred to our hospital following a motor vehicle accident. Upon arrival to the emergency room (ER), the patient was in hypotensive shock which required a cardiovascular resuscitation. Following stabilization, clinical evaluations and imaging were performed. There were gross deformities in the lower limb (both leg and thigh) without any neurovascular problems. The imaging of the pelvis [plain radiographs and computed tomography (CT) scan] showed pelvic ring injury with anteroposterior compression (APC) type III, which consisted of the left side sacroiliac joint (SIJ) disruption posteriorly, and T-Type fracture-dislocation (central) of the left acetabulum, anteriorly. A transverse fracture of the left femur and segmental fractures of the left tibia and fibula were detected (Figures 1-4).

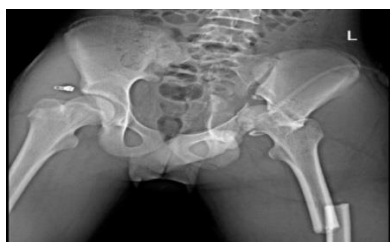

Figure 1. Preoperative anteroposterior (AP) radiograph of the pelvis

There were some skin abrasions over the thigh and leg (Tscherne type 1), but there was no wound. Abdomen and chest showed no problem. There was no sign or symptom of head and spine injury.

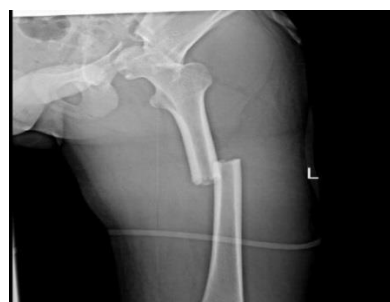

Figure 2. Preoperative anteroposterior (AP) radiograph of the femur

We planned to start fixation from proximal to distal. Under general anesthesia and using the iliac fossa approach in the supine position, we reduced and fixed the left SIJ with plate and screws. Then, we used the Stoppa approach with the application of lateral and distal traction to the proximal femur with Schanz screw.

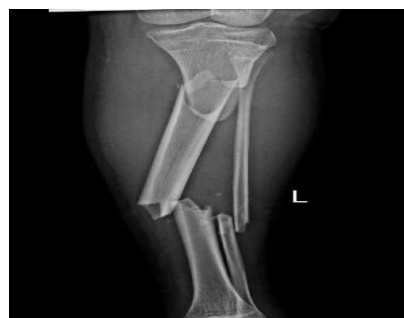

Figure 3. Preoperative anteroposterior (AP) radiograph of the tibia

The head of the femur and quadrilateral plate of the acetabulum were reduced and fixed with a buttress plate.

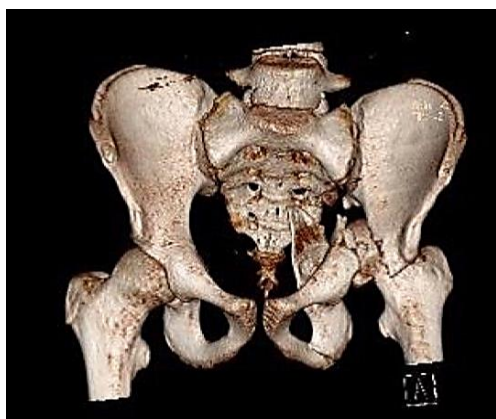


Figure 4. Pelvic computed tomography (CT) scan

Then the patient's position was changed to lateral decubitus. By the posterior approach to the acetabulum, the posterior column was fixed with a plate and screw. In the same position with the same approach from the piriformis fossa, a femoral antegrade intramedullary nail (IMN) was inserted. After two days in the supine position, a closed IMN was inserted for the segmental fracture of the tibia (Figures 5-8).

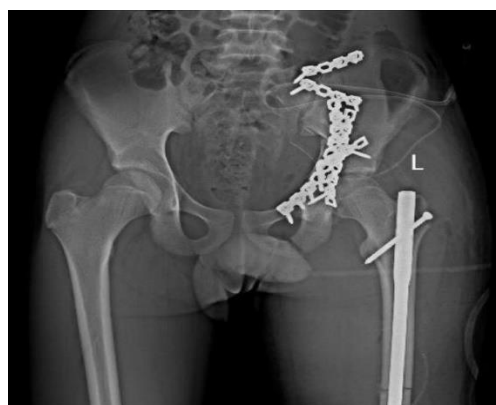

Figure 5. Postoperative anteroposterior (AP) radiograph of the pelvis

According to our routine follow up protocol, the patient was visited postoperatively at the intervals of 1 week, 1 month, 3 months, 6 months, and yearly thereafter.

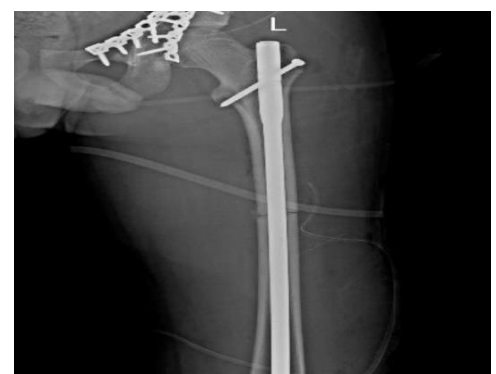

Figure 6. Postoperative anteroposterior (AP) radiograph of the femur

At the 24th month, post-traumatic joint degeneration in the hip joint was detected clinically and radiographically, which was scheduled for total hip arthroplasty.

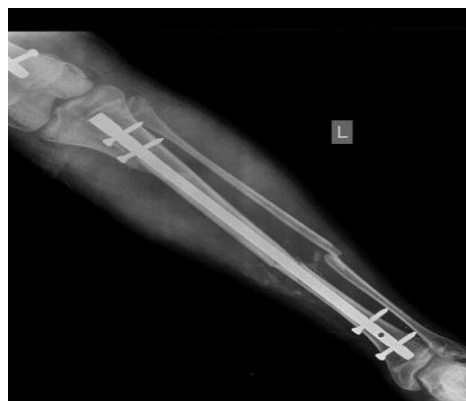

Figure 7. Postoperative anteroposterior (AP) radiograph of the tibia

At the 6th month, the union of all fractures was completed and range of motion (ROM) was full in the hip, knee, and ankle joints.

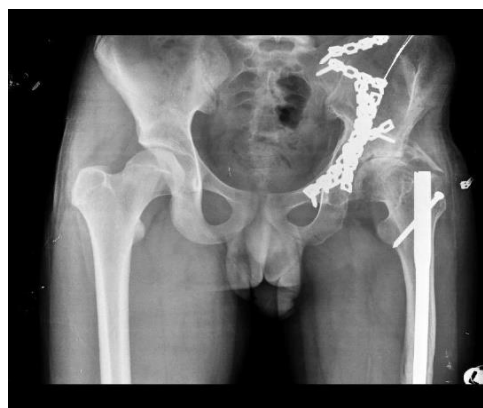

Figure 8. Pelvic anteroposterior (AP) radiographs 15 months after surgery

Discussion

The simultaneous floating hip and knee injury is a rare condition, reported by a few authors (1, 2). To the best of our knowledge, the best order of fixation in this complicated situation is not yet defined. We believe that for the best outcome, the treatment protocol should yield less bleeding, transfusion, and hospital stay, as well as an early mobilization. Decreasing the number of surgeries could result in less bleeding and transfusion. Additionally, treating more fractures in a single-event surgery (if applicable) shortens the hospital stay and accelerates the rehabilitation program. Liebergall et al. have advocated the initial and definitive femoral fixation with early mobilization (1).

We preferred to start the fixation from the most proximal fractures (sacroiliac joint) because it can stabilize and connect the pelvis to the central part of the body, forming a stable foundation for other fixations. Moreover, anatomic reduction of the acetabular fracture may be disturbed by even a slight malreduction in the pelvic ring (5). Then, fracture of the quadrilateral plate and central fracture-dislocation of the hip were reduced, and the quadrilateral plate and anterior column were fixed with buttress plating via the Stoppa approach. This

approach worked well here because we could hold the quadrilateral plate with an intrapelvic 90-degree bent buttress plate. The only remaining part of the acetabulum was the rotated posterior column. We preferred to do posterior fixation via the posterior approach, and at the same time, insert the antegrade IMN. Not only it saves time, but also it combines antegrade nailing of the femur through the similar approach.

No standard guideline for treatment of ipsilateral floating knee and hip has been determined so far. We recommend to start the fixation from proximal and stabilize the pelvic ring at first. Then, fix the posterior part of the acetabulum and femoral shaft with the same posterior approach.

Conclusion

Due to our discussed experience, We recommend order of fixation to be started from proximal in the future similar cases and emphasize on optimized pelvic and acetabular reduction to be the most important task for orthopedic surgeons when facing the same fracture as ours.

Conflict of Interest

The authors declare no conflict of interest in this study.

Acknowledgments

We would like to appreciate Miss Elnaz Amani, Educational Secretary of Orthopedic Ward, Sina Hospital, Tehran, Iran for her kind contribution in data collection in this study.

References

1. Liebergall M, Lowe J, Whitelaw GP, Wetzler MJ, Segal D. The floating hip. Ipsilateral pelvic and femoral fractures. *J Bone Joint Surg Br.* 1992;74(1):93-100. doi: [10.1302/0301-620X.74B1.1732275](https://doi.org/10.1302/0301-620X.74B1.1732275). [PubMed: [1732275](https://pubmed.ncbi.nlm.nih.gov/1732275/)].
2. Liebergall M, Mosheiff R, Safran O, Peyser A, Segal D. The floating hip injury: Patterns of injury. *Injury.* 2002;33(8):717-22. doi: [10.1016/S0020-1383\(01\)00204-2](https://doi.org/10.1016/S0020-1383(01)00204-2). [PubMed: [12213424](https://pubmed.ncbi.nlm.nih.gov/12213424/)].
3. Lundy DW, Johnson KD. "Floating knee" injuries: Ipsilateral fractures of the femur and tibia. *J Am Acad Orthop Surg.* 2001;9(4):238-45. doi: [10.5435/00124635-200107000-00003](https://doi.org/10.5435/00124635-200107000-00003). [PubMed: [11476533](https://pubmed.ncbi.nlm.nih.gov/11476533/)].
4. Hackla S. Case of Ipsilateral Floating Hip and Floating Knee- A Rare Injury. *International Journal of Advanced Research.* 2015;3(7):483-8.
5. Letournel E, Judet R. Fractures of the acetabulum. Berlin, Germany: Springer Science & Business Media; 2012.