

Different Scenarios of Asymptomatic Coronavirus Disease 2019 in Orthopedic Trauma Patients: Case Series and Practical Guide

Seyyed Hossein Shafiei^{1*}, Salar Baghbani², Mohsen Rezaei Nosrati², Babak Siavashi³,
Mohammad Reza Golbakhsh³

¹ Assistant Professor, Department of Orthopedic Surgery, Sina Hospital, School of Medicine, Tehran University of Medical Sciences, Tehran, Iran

² Resident, Department of Orthopedic Surgery, Sina Hospital, School of Medicine, Tehran University of Medical Sciences, Tehran, Iran

³ Associate Professor, Department of Orthopedic Surgery, Sina Hospital, School of Medicine, Tehran University of Medical Sciences, Tehran, Iran

*Corresponding author: Seyyed Hossein Shafiei; Department of Orthopedic Surgery, Sina Hospital, School of Medicine, Tehran University of Medical Sciences, Tehran, Iran. Tel: +98-2163121297, Email: dr_hshafiei@yahoo.com

Received: 01 March 2020; Revised: 27 April 2020; Accepted: 19 May 2020

Abstract

Background: During the outbreak of the novel coronavirus disease 2019 (COVID-19), Sina Hospital in Tehran, Iran, dedicated a majority of its facilities and workforce to fight this crisis. Meanwhile, our academic trauma center continued to admit emergency trauma patients.

Case Report: In this case series, we tried to discuss five previously healthy trauma patients who underwent orthopedic surgery and were diagnosed with COVID-19 later. Also, we described our detailed protocol for the management of orthopedic patients during the pandemic.

Conclusion: During COVID-19 time, we continued to provide our best service to the trauma patients while keeping our personnel as far as possible from direct contact with the patients until it was necessary.

Keywords: COVID-19; Coronavirus; Trauma; Orthopedics; Pandemic

Citation: Shafiei SH, Baghbani S, Rezaei Nosrati M, Siavashi B, Golbakhsh MR. **Different Scenarios of Asymptomatic Coronavirus Disease 2019 in Orthopedic Trauma Patients: Case Series and Practical Guide.** *J Orthop Spine Trauma* 2020; 6(2): 43-7.

Background

The novel coronavirus disease 2019 (COVID-19) is a highly contagious, fast-spreading virus that can cause extreme expenses to the people and the medical system (1). Since the first reports of COVID-19 in Iran, our hospital committee took action to control the outbreak. As we perceived the situation as a crisis, all elective activities in our ward were postponed to a steadier time and the majority of hospital facilities were dedicated to COVID-19. However, our hospital is a referral trauma center and we had to continue our service in emergency cases such as orthopedic fractures. For this purpose, we needed to define new protocols for patients with an emergent need to fixation, as well as ligamentous or nerve injuries caused by stab wounds and infections, especially around the joints.

In Tehran, Iran, the COVID-19 started to become an eminent problem since the last days of February 2020. Since then, we have made an algorithm for our educational and healthcare activities to minimize exposure for our orthopedic surgery team. From January to June 2020, we executed about 600 orthopedic surgeries and admitted more than 400 orthopedic trauma patients. During this period, only one of our orthopedic surgery residents out of 13 caught the COVID-19 which is a promising outcome compared to the other two educational hospitals of our university (14 out of 18 orthopedic surgery residents in one and 6 out of 13 in the other).

Like every other pulmonary virus, the coronavirus has a certain incubation period which makes us unable to declare a patient free from the viral infection using physical examination and history alone (2). Since the outbreak began, we started to evaluate patients which needed longer hospital stay by using a combination of

history taking, physical examination, imaging, and laboratory findings (3, 4). The radiologic studies consisted of a plain chest X-ray for every trauma patient, the same as before the outbreak, and a chest computed tomography (CT) scan in suspicious cases (3). After facing several problems in identifying positive patients, we revised our diagnostic studies and became more cautious.

In this article, we aim to present five of our patients with positive polymerase chain reaction (PCR) test for COVID-19, who simultaneously had emergent orthopedic problems requiring further hospitalization and surgery. Also, we describe our detailed protocol for the management of orthopedic patients during the COVID-19 pandemic.

Case Report

All medical data were used after obtaining consent from the patient or his legal representative. These five cases were selected out of 50 patients admitted to the orthopedic surgery emergency room (ER) from February 22 to March 13, 2020 (10% of our trauma admission in 3 weeks).

Case 1: A 20-year-old man was brought to the ER by emergency medical services (EMS), complaining from left carpal tenderness and deformity. Due to initial radiologic findings, perilunate dislocation was confirmed and two attempts to reduce the dislocation by Tavernier's maneuver failed in the ER (5). Under sedation and close cardiac monitoring, the reduction attempt was performed again by the emergency team. All personnel followed routine hospital protocols for self-protection (hand gloves and N95 face mask) which were re-defined after the COVID-19 outbreak. Finally, the patient was scheduled for surgery and an open reduction was performed under general anesthesia (GA) by the orthopedic surgery team including

a hand surgeon.

Based on an initial clear chest X-ray, no additional protective measures were taken by the personnel during the surgery and patient's hospital stay. After the surgery, the patient experienced shortness of breath and low-level fever. Additional workups showed definitive clues for COVID-19 in the chest CT and PCR test. He was hospitalized for five days after the surgery and was discharged after the alleviation of pulmonary symptoms. Figure 1 shows pre- and postoperative imaging. This scenario made all medical staff and especially the orthopedic surgery ward more cautious about the self-protection measures.

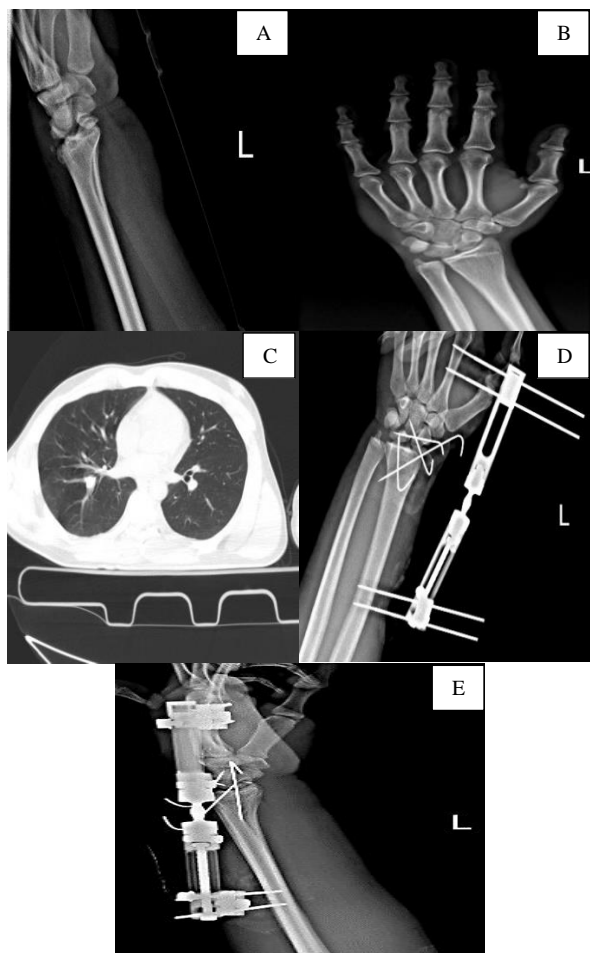


Figure 1: Case 1: A and B) preoperative radiographs of the patient, C) chest computed tomography (CT) scan, D and E) postoperative radiographs

Case 2: A 38-year-old man was presented to the ER, with initial examinations in accordance with open 4th metacarpal fracture. The patient was admitted for surgery. He declared no known medical problems.

Because of mild breath shortness and low-grade fever, a plain chest X-ray and CT scan were obtained, in addition to laboratory studies, which eventually led to COVID-19 diagnosis (Figure 2). Patient was transferred to the COVID-19 ward and special care was taken during every step of the following medical care he received. Under local anesthesia, we performed metacarpal pinning by the least number of required medical staff and the most available self-protection. As the surgery was inevitable, the senior surgery resident did the operation in about 15 minutes to minimize the exposure time. The patient was discharged

in a good condition after passing the initial pulmonary phase of the COVID-19.

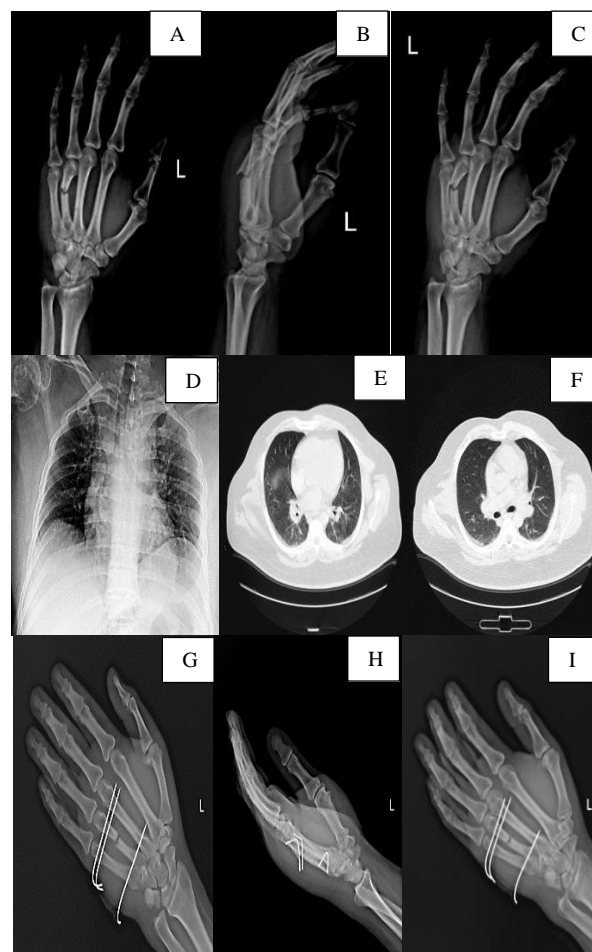


Figure 2: Case 2: A-C) preoperative radiographs of the patient, D) chest X-ray, E and F) chest computed tomography (CT) scan, G-I) postoperative radiographs

Case 3: A 27-year-old man was brought to the ER after a motor vehicle accident (MVA) by pain and deformity in the right femoral shaft and ipsilateral knee. His past medical history was unremarkable. On initial diagnostic workups, we detected fractures of the right femoral shaft and patella. The patient had no signs and symptoms suggestive for COVID-19 involvement. Therefore, the emergency team avoided more diagnostic tests which seemed a waste of energy and money according to the outbreak's policy to minimize unnecessary expenses.

On the other hand, due to high-energy trauma, our general surgery team decided to obtain thoraco-abdominopelvic CT scan to rule out possible damage to the abdominal cavity and chest. The CT scan showed no surgical issues but revealed high grade of reticulation in the lungs, suggestive for COVID-19. Additional studies such as complete blood count (CBC), erythrocyte sedimentation rate (ESR), and C-reactive protein (CRP) made us more suspicious of COVID-19 asymptomatic involvement. Thus, we optimized our self-protection facilities in the operating room (OR). The operation was executed by two of our senior residents accompanied by an attending fellow to reduce the surgery time and exposure as much as possible. The femoral shaft and patella were fixed by intramedullary nailing and tension band wiring (TBW) under GA (Figure 3).

The PCR test came back positive after the surgery.

Due to desaturation after the surgery, the patient was admitted to the intensive care unit (ICU) and intubated for 4 days. He eventually started to improve, extubated, and transferred to COVID-19 ward after 15 days of ICU admission. He was discharged 20 days after the surgery in a good condition while starting toe-touch weight-bearing. This case made our medical staff even more cautious and pessimistic on every single patient, even if there was no clue for viral involvement in initial workups.

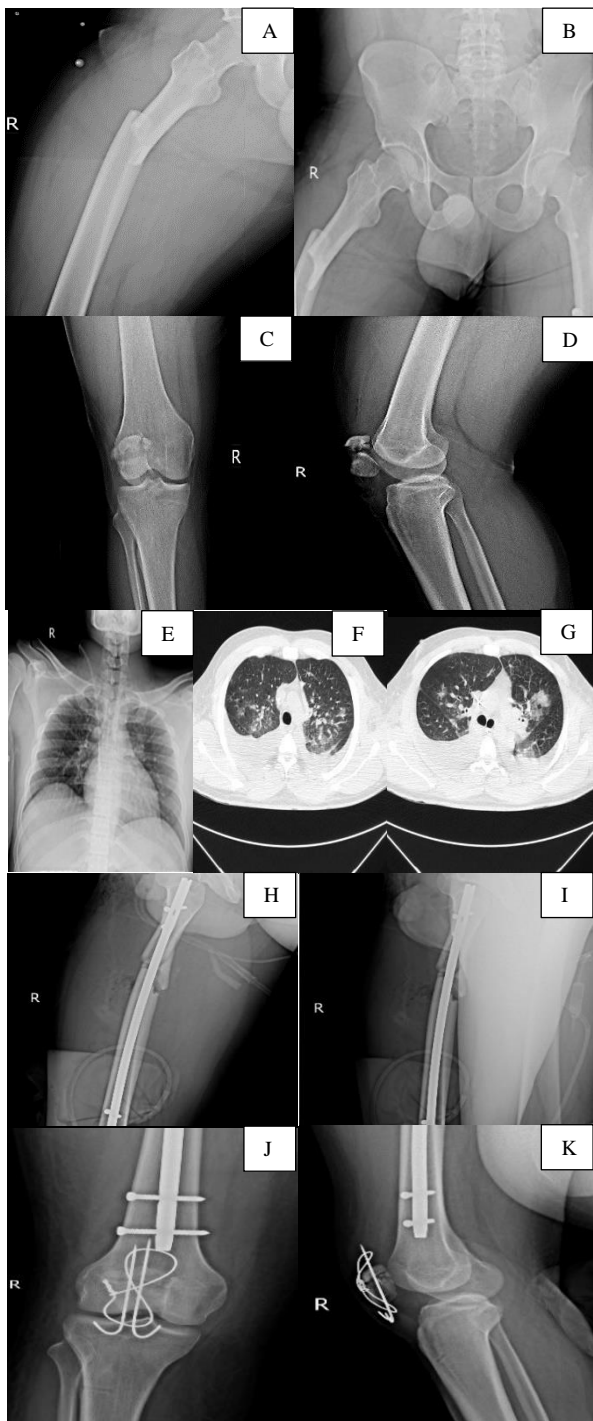


Figure 3: A-D) preoperative radiographs of the patient, E) chest X-ray, F and G) chest computed tomography (CT) scan, H-K) postoperative radiographs

Case 4: A 17-year-old man experiencing a MVA was diagnosed with a left subtrochanteric fracture. The patient had no clinical signs and symptoms of COVID-19 but the CBC showed leukocytosis. The suspicion was strengthened by the thoraco-abdominopelvic CT scan which was primarily ordered to exclude intrathoracic and intra-abdominal injuries due to the trauma mechanism. Until the PCR test results were back (3 days), we treated the patient as a positive COVID-19 case and transferred him to the isolated room. A proximal femoral nail was placed for the patient under the self-protection protocols which were implanted for COVID-19 (Figure 4).

Moreover, the surgery was performed by one of our senior residents accompanied by a hip surgeon to minimize the exposure time.

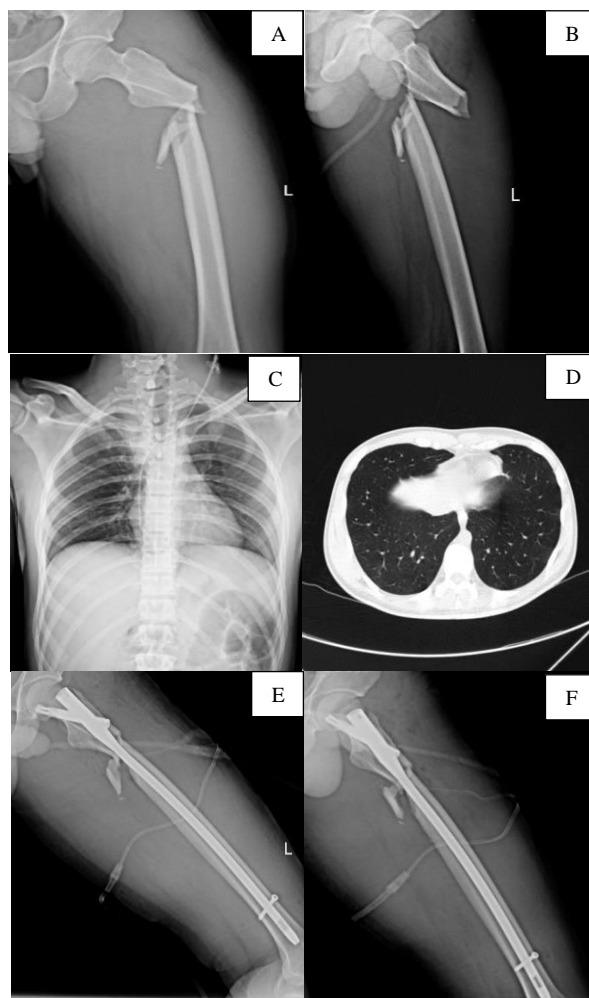


Figure 4: Case 4: A and B) preoperative radiographs of the patient, C) chest X-ray, D) chest computed tomography (CT) scan, E and F) postoperative radiographs

The PCR test came back positive and the patient was transferred to COVID-19 ward. He was discharged 5 days after the surgery with good condition.

Case 5: A 27-year-old man was brought to the ER by EMS following a MVA. In initial evaluations, he had a left femoral shaft fracture, left distal femoral fracture, left open knee fracture, left distal radius fracture, and an open book pelvic fracture (Figure 5).

The patient was unconscious on admission. Bilateral chest tubes were inserted due to pneumothorax and he

was transferred to the ICU, requiring massive transfusion. The initial orthopedic surgery measures included irrigation of the open knee injury, distal tibial skeletal traction for the left lower extremity, fixation of the left wrist by a splint, and stabilization of the pelvis by a pelvic binder. The patient stayed in the ICU for 5 days. The initial CT scan was clear, without any evidence of COVID-19. The patient's temperature elevated during the ICU admission. On the fifth day of ICU admission, the neurosurgery team confirmed the diagnosis of brain death. The next day after his death, the PCR test came back positive. It is unclear for us whether the patient caught COVID-19 in the hospital or before the injury.

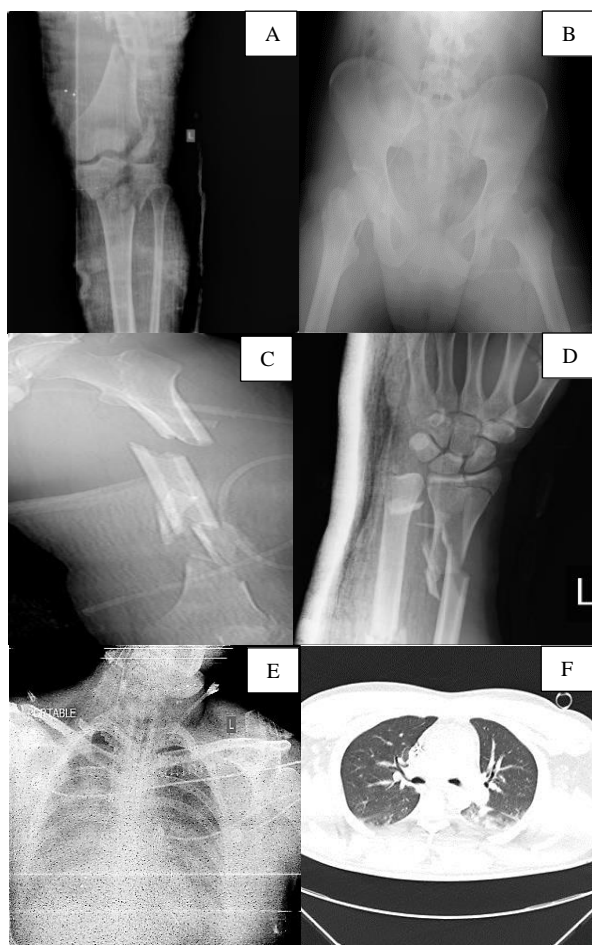

Figure 5. Case 5: A-D) preoperative radiographs of the patient, E) portable chest X-ray, F) chest computed tomography (CT) scan

Discussion

To control an outbreak, like the present circumstances which the world is facing right now, every single unit in the healthcare system should dedicate its properties and activities (6). However, many orthopedic fractures could not be postponed and need to be managed without any hesitation.

All the patients in our study were men under 40 years of age and had a previous healthy status, which helped them to overcome the viral infection (4 out of 5) (7). As our hospital is a trauma center, most of our cases were brought by EMS after MVAs. Postponing the surgical treatment in all of these cases was impossible according to

the characteristics of the fractures. The mortality rate in our cases was only one in five. The deceased case died probably due to a high-energy trauma and brain injury.

Since the infection can be asymptomatic, we came to the conclusion that every patient could be a COVID-19 case. Therefore, it is safer to maintain reasonable self-protection measures for every involved medical staff and to minimize the number of healthcare workers who are directly involved in the patient's surgical care (3, 8).

The chest X-ray might not show any abnormality even in mild to severe COVID-19 pneumonia (9). We have benefited from a detailed history taking, physical examination, initial chest X-ray, as well as lab tests such as CBC, ESR, and CRP. In any suspected case, we performed a chest CT scan and PCR.

In 2 of our cases, the chest CT scan was performed due to high-energy trauma, and not because of COVID-19 suspicion. Such experiences made our medical staff more cautious and brought the threshold of ordering a CT scan much lower.

Our Protocol

The scenarios discussed were our very first experiences on COVID-19 in the first 3 weeks of the outbreak in Tehran. So, we may have underestimated the virus's power, especially the long incubation period. Since then, Sina Hospital's orthopedic surgery team has faced an overreaction, considering every patient a positive case. This situation required a plan to minimize both the expenses while reducing the high risk of exposure to the virus. Eventually, through brainstorming and literature review, we managed to successfully implement preventive policies, which are described here.

1. Education: As educating new specialists has been a valuable priority since the beginning of Sina Hospital's orthopedic surgery ward, we could not postpone the educational sessions. We used Skype application for educational sessions, once in the early morning and once in the afternoon. Every resident was encouraged to cooperate actively in every session. Also, the routine exams were held in the same manner to keep the trainees fresh. This program has continued to date and reduced a remarkable amount of exposure.

2. Night Shifts: In order to minimize the exposure, we reduced the night shifts in the ER to the least available number. The first-year residents who had 15 night shifts a month before were rearranged to do 6 nights monthly. Instead, they were reserved for 6 on-call shifts in which if their colleague needed help, they had to come to the hospital. The second- and third-year residents had 10 night shifts per month and supervised the ER on routine hours to minimize the stay of patients in the ER.

According to the high risk of catching the virus in the ER from asymptomatic patients, we defined a rule to transfer every patient to the ward during the first 2 hours of arrival.

3. Clinic: Our postoperative visits were minimized to the possible extent. To reach this goal, we have used telephone visits. There was no hesitation to schedule an in-person visit when needed. Due to our protocol, every trauma patient who needed a postoperative X-ray had to visit on one month. Our clinic staff used a fast admitting system for the outpatients, during which the name and telephone number of the patient were added to the system in less than 1 minute. Other required information was collected later via a phone call.

For yearly visits, we called the patient, and if no problem

existed, the visit was postponed to a suitable time.

4. *Ward:* Postoperative patients spent the minimum time feasible in the ward and most of them were discharged the day after. A 24/7 telephone number was available to answer the patient's questions by our residents. The physiotherapy and postoperative care were thoroughly explained for the patients and their families with videos and visual aids to minimize the visits. The routine ward rounds were stopped and all visits were conducted by one or two residents and attending fellow to reduce the physical exposure.

5. *OR:* Every day, all surgeries were scheduled by the chief resident due to the complexity of the fracture and the patient's status. If there was a definitive or suspicious diagnosis of coronavirus infection, the time of surgery was reduced by putting the most experienced surgeon in charge of the surgery.

Conclusion

Asymptomatic COVID-19 can mislead the healthcare providers and put them in a high risk of infection. As a trauma center in Tehran, most of our patients were trauma victims of MVAs and in many cases, there was no time to see the results of the COVID-19 PCR test before the surgery. Based on the high number of patients we have managed since the beginning of COVID-19 and the low rate of corona infection among our residents, we believe that preventive measures implemented in our hospital were quite effective.

Conflict of Interest

The authors declare no conflict of interest in this study.

Acknowledgments

We would like to appreciate Miss Elnaz Amani, educational secretary of Sina Hospital Orthopedic ward, for her fine contribution in collecting data in this study.

References

1. Severe Outcomes Among Patients with Coronavirus Disease 2019 (COVID-19)-United States, February 12-March 16, 2020. *MMWR Morb Mortal Wkly Rep.* 2020;69(12):343-6. doi: [10.15585/mmwr.mm6912e2](https://doi.org/10.15585/mmwr.mm6912e2). [PubMed: [32214079](https://pubmed.ncbi.nlm.nih.gov/32214079/)].
2. Nishiura H, Kobayashi T, Miyama T, Suzuki A, Jung SM, Hayashi K, et al. Estimation of the asymptomatic ratio of novel coronavirus infections (COVID-19). *Int J Infect Dis.* 2020;94:154-5. doi: [10.1016/j.ijid.2020.03.020](https://doi.org/10.1016/j.ijid.2020.03.020). [PubMed: [32179137](https://pubmed.ncbi.nlm.nih.gov/32179137/)]. [PubMed Central: [PMC7270890](https://pubmed.ncbi.nlm.nih.gov/PMC7270890/)].
3. Fang Y, Zhang H, Xie J, Lin M, Ying L, Pang P, et al. Sensitivity of Chest CT for COVID-19: Comparison to RT-PCR. *Radiology.* 2020;296(2):E115-E117. doi: [10.1148/radiol.2020200432](https://doi.org/10.1148/radiol.2020200432). [PubMed: [32073353](https://pubmed.ncbi.nlm.nih.gov/32073353/)]. [PubMed Central: [PMC7233365](https://pubmed.ncbi.nlm.nih.gov/PMC7233365/)].
4. Gostic K, Gomez AC, Mummah RO, Kucharski AJ, Lloyd-Smith JO. Estimated effectiveness of symptom and risk screening to prevent the spread of COVID-19. *Elife.* 2020;9:e55570. doi: [10.7554/eLife.55570](https://doi.org/10.7554/eLife.55570). [PubMed: [32091395](https://pubmed.ncbi.nlm.nih.gov/32091395/)]. [PubMed Central: [PMC7060038](https://pubmed.ncbi.nlm.nih.gov/PMC7060038/)].
5. Reisler T, Therattil PJ, Lee ES. Perilunate dislocation. *Eplasty.* 2015;15:ic9. [PubMed: [25671060](https://pubmed.ncbi.nlm.nih.gov/25671060/)]. [PubMed Central: [PMC4321386](https://pubmed.ncbi.nlm.nih.gov/PMC4321386/)].
6. Toner E, Waldhorn R, Maldin B, Borio L, Nuzzo JB, Lam C, et al. Hospital preparedness for pandemic influenza. *Biosecure Bioterror.* 2006;4(2):207-17. doi: [10.1089/bsp.2006.4.207](https://doi.org/10.1089/bsp.2006.4.207). [PubMed: [16792490](https://pubmed.ncbi.nlm.nih.gov/16792490/)].
7. Zhou F, Yu T, Du R, Fan G, Liu Y, Liu Z, et al. Clinical course and risk factors for mortality of adult inpatients with COVID-19 in Wuhan, China: A retrospective cohort study. *Lancet.* 2020;395(10229):1054-62. doi: [10.1016/S0140-6736\(20\)30566-3](https://doi.org/10.1016/S0140-6736(20)30566-3). [PubMed: [32171076](https://pubmed.ncbi.nlm.nih.gov/32171076/)]. [PubMed Central: [PMC7270627](https://pubmed.ncbi.nlm.nih.gov/PMC7270627/)].
8. Wong KC, Leung KS, Hui M. Severe acute respiratory syndrome (SARS) in a geriatric patient with a hip fracture. A case report. *J Bone Joint Surg Am.* 2003;85(7):1339-42. doi: [10.2106/00004623-200307000-00022](https://doi.org/10.2106/00004623-200307000-00022). [PubMed: [12851360](https://pubmed.ncbi.nlm.nih.gov/12851360/)].
9. Hosseiny M, Kooraki S, Gholamrezanezhad A, Reddy S, Myers L. Radiology perspective of coronavirus disease 2019 (COVID-19): Lessons from severe acute respiratory syndrome and middle east respiratory syndrome. *AJR Am J Roentgenol.* 2020;214(5):1078-82. doi: [10.2214/AJR.20.22969](https://doi.org/10.2214/AJR.20.22969). [PubMed: [32108495](https://pubmed.ncbi.nlm.nih.gov/32108495/)].