

Asymptomatic Coronavirus Disease 2019 in Patients with Trauma: A Report of Three Cases in a General Hospital

Seyed Mohammad Javad Mortazavi¹, Seyed Hadi Kalantar^{2,*}, Nima Shahryarpour³

¹Professor, Department of Orthopedic Surgery, Joint Reconstruction Research Center, Tehran University of Medical Sciences, Tehran, Iran

²Assistant Professor, Department of Orthopedic Surgery, Joint Reconstruction Research Center, Tehran University of Medical Sciences, Tehran, Iran

³Specialist in Emergency Medicine, School of Medicine, Tehran University of Medical Sciences, Tehran, Iran

*Corresponding author: Seyed Hadi Kalantar; Department of Orthopedic Surgery, Joint Reconstruction Research Center, Tehran University of Medical Sciences, Tehran, Iran. Tel: +98-9126110015, Email: hadikalantar4@gmail.com

Received: 14 January 2020; Revised: 27 February 2020; Accepted: 12 April 2020

Abstract

Background: Patients with asymptomatic coronavirus disease 2019 (COVID-19) can transmit the disease to others. Since the trauma patients represent a portion of society and can be asymptomatic carriers of COVID-19, it is essential for medical staff to use precautions when managing all trauma patients with or without symptoms of COVID-19.

Case Report: In this article, we discuss three patients with bone fractures who had no previous symptoms of COVID-19. Two cases were old patients with intertrochanteric fractures, and the other one was a young man with a distal clavicular fracture. All patients were diagnosed incidentally in the course of the admission.

Conclusion: Emergency room (ER) personnel and orthopedic surgeons should be aware of asymptomatic COVID-19 cases. It is important to use standard personal protective equipment (PPE) during the evaluation of all patients with orthopedic trauma to prevent disease spread.

Keywords: COVID-19; Orthopedics; Trauma; Bone Fractures; Asymptomatic Diseases

Citation: Mortazavi SMJ, Kalantar SH, Shahryarpour N. **Asymptomatic Coronavirus Disease 2019 in Patients with Trauma: A Report of Three Cases in a General Hospital.** *J Orthop Spine Trauma* 2020; 6(2): 39-42.

Background

In the last hours of the past decade, Chinese health authorities reported that a new respiratory disease caused by severe acute respiratory syndrome coronavirus 2 (SARS-CoV-2) has emerged, which was later called coronavirus disease 2019 (COVID-19). Spreading at an alarmingly high rate, the COVID-19 was recognized as a pandemic by the World Health Organization (WHO) after infecting a majority of countries worldwide (1).

Currently, the universally accepted method of diagnosis for COVID-19 is the reverse transcription-polymerase chain reaction (RT-PCR). However, there is a limitation to this method, since the sensitivity of the test is down to 60% (2, 3). The idea that every individual can be a silent carrier of COVID-19 has concerned healthcare providers, especially after that the Chinese Center for Disease Control and Prevention reported that 1.0-1.2 percent of positive RT-PCR cases were asymptomatic (4). This horrifying fact that the disease can also easily spread from asymptomatic individuals to others puts healthcare providers at high risk (5-7).

In this article, we present three asymptomatic patients with COVID-19 who were referred to our center with a history of trauma and orthopedic complaint. Then we discuss the upcoming challenges.

Case Report

Informed consent was obtained from all patients.

Case 1: A 66-year-old woman was brought to our hospital with a history of falling on the right side of the pelvis and inability to move her right leg and pain in the right hip. She

had a history of well-controlled coronary artery disease (CAD) and diabetes mellitus (DM). Vital signs and pulmonary auscultation were normal. There was no history of respiratory distress, coughs, fever, or fatigue. On initial evaluation, we performed a pelvic x-ray and she was diagnosed with a right intertrochanteric fracture (Figure 1).

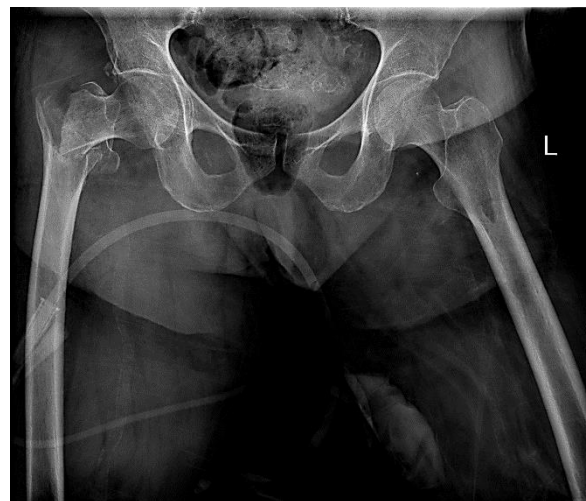

Figure 1. Case No. 1: intertrochanteric fracture in a patient with no symptoms of coronavirus disease 2019 (COVID-19)

As a part of the preoperative evaluations, the anesthesiologist requested a chest x-ray (CXR). Multiple bilateral patchy opacities were found on the CXR. The patient underwent a chest computed tomography (CT)

scan to investigate lung involvement. The CT scan showed bilateral multi-lobar ground-glass opacities (GGOs) in the peripheral zone, which are highly suggestive of COVID-19 (Figure 2).

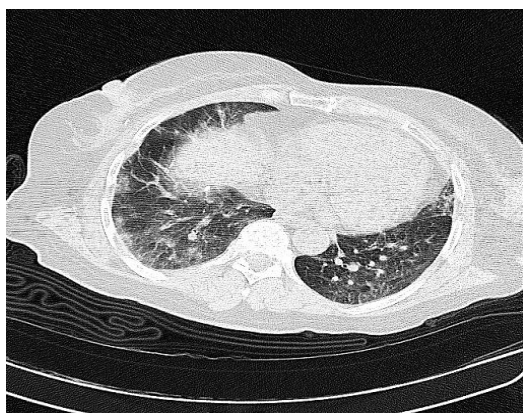

Figure 2. Case No. 1: computed tomography (CT) scan showing bilateral multi-lobar ground-glass opacities (GGOs) in the peripheral zone suggesting coronavirus disease 2019 (COVID-19)

Due to her risk factors and past medical history, our infectious disease specialist decided to admit her in the COVID-19 ward. A positive RT-PCR test confirmed the diagnosis. She developed respiratory distress later in the course of the disease and was admitted to the intensive care unit (ICU). Our intensivists prevented us from performing an early orthopedic surgical intervention. Therefore, the open reduction internal fixation (ORIF) with dynamic hip screw (DHS) was performed on the 7th day of admission. She recovered from the severe COVID-19 after 14 days of hospitalization in the ICU. We discharged her from the hospital with a fair condition. The first follow-up visit was performed through our virtual office system (VOS). The patient is now mobilized, and she has less complaints about coughs and dyspnea.

Case 2: A 30-year-old man presented to the emergency room (ER) after sustaining trauma to his left shoulder due to a car accident. The patient complained of a pain in his left shoulder along with confusion. He had no previous medical or drug history. The patient's vital signs were normal. We performed trauma series, left shoulder x-ray, and a brain CT to rule out the possible injuries. There were peripheral opacities of both lungs on his CXR, along with a distal clavicular fracture (Figure 3).

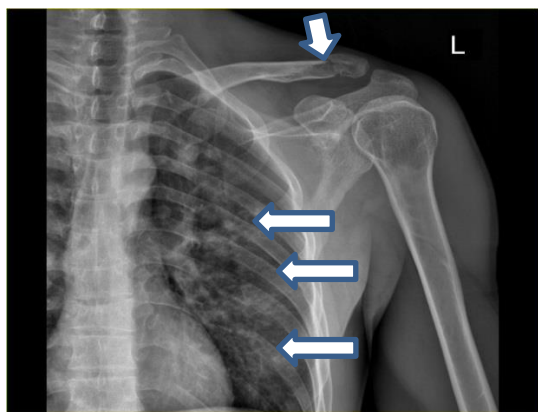


Figure 3. Case No. 2: long arrows showing peripheral opacities of both lungs, short arrow showing a distal clavicular fracture on the chest x-ray (CXR)

On the chest spiral CT scan, multiple peripheral multi-lobar opacities on both lungs suggested the lung involvement of COVID-19 (Figure 4). The patient was admitted to the COVID-19 quarantine ward. A nasal swab specimen for the RT-PCR test was taken which came back negative for COVID-19. Asking further questions from the patient and his family did not help to find a history of close contact with a confirmed case of COVID-19. He refused to undergo the surgical treatment for his distal clavicular fracture and was discharged with an arm sling. Based on infectious disease consultation, we decided to quarantine the patient at home with hydroxychloroquine treatment and contact precautions for his family members. Using telecommunication, we followed the patient after five days. He sustained dry coughs, low-grade fever, and malaise two days after discharge, but had no complaints of shortness of breath.

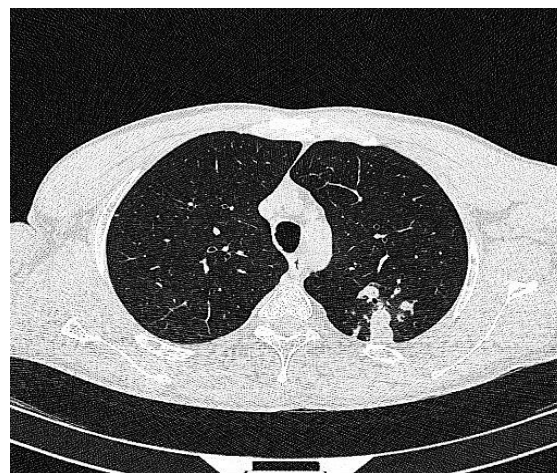

Figure 4. Case No. 2: lung computed tomography (CT) scan of the patient with clavicular fracture and incidental opacities on the chest x-ray (CXR) showing peripheral lung involvements in favor of coronavirus disease 2019 (COVID-19)

Case 3: A 90-year-old woman was admitted to the ER with an intertrochanteric fracture due to falling (Figure 5).

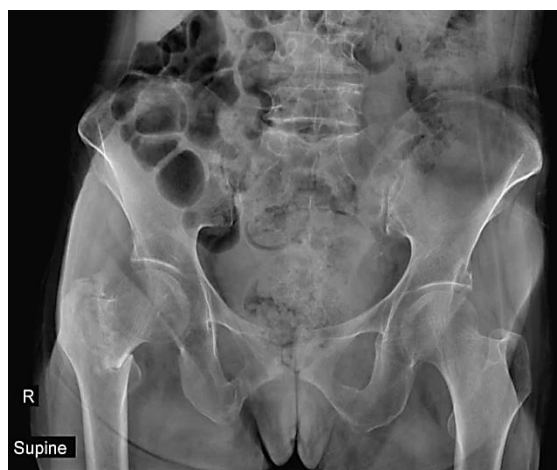

Figure 5. Case No. 3: the pelvic x-ray of the patient showing a right intertrochanteric fracture

In the primary evaluations, she did not complain of any respiratory symptoms. Her vital signs were normal. She had a history of close contact with a COVID-19 patient a week ago. She underwent a lung CT scan and a throat swab for RT-PCR

test. On the lung CT scan, there were typical signs of COVID-19 involvement (Figure 6). The RT-PCR was positive for COVID-19. Due to the past medical history of DM and hypertension (HTN), the anesthesiologist did not permit the operation and the patient was admitted for observation. Two days later, the patient was admitted to the ICU after developing respiratory symptoms and low blood oxygen saturation. Unfortunately, she did not respond to medical treatment and passed away two days later.

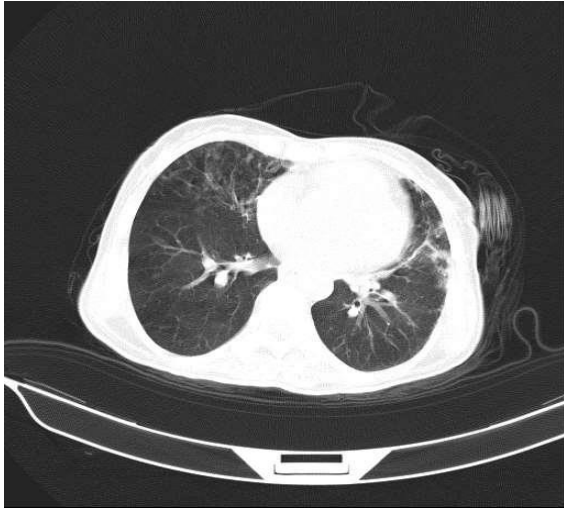


Figure 6. Case No. 3: lung computed tomography (CT) scan of the patient showing typical lung involvements in favor of coronavirus disease 2019 (COVID-19)

Discussion

COVID-19 is now a pandemic and is believed to stay with human society for several months. Up to now, there is not enough knowledge to predict whether the human race can eradicate the disease or not. We also cannot predict the time of production of an effective vaccine for this virus.

Our study showed that any patient with orthopedic trauma and fracture who presents to the ER during the COVID-19 epidemic could be an asymptomatic carrier. The Chinese healthcare providers stated that early clinical manifestation of the disease in most patients in Wuhan (where the outbreak is assumed to have started) was fever, fatigue, and dry cough (8). However, there are several reports of potential transmission of the disease from an asymptomatic carrier. All three patients in our study did not have any symptoms before hospitalization. It means that they could have spread the virus further to others if the traumatic accident had not forced them to seek medical attention.

There is considerable concern about exposing healthcare providers who are managing trauma patients in ERs and operating rooms (ORs) regarding the asymptomatic and undetected patients with COVID-19. However, there is no consensus on how to screen ER patients with a fracture for COVID-19 infection if they have no symptoms. The main diagnostic tests for COVID-19 are spiral CT scan and RT-PCR. The sensitivity and specificity for RT-PCR test, which is the gold standard for diagnosing COVID-19, are relatively low (2, 3). Moreover, in deprived areas, the test is sent out which can take a few days before the results are ready.

There are newly introduced rapid antibody tests and even RT-PCR with higher accuracy for screening both

symptomatic and asymptomatic patients (9, 10). Unfortunately, all trauma centers and hospitals which admit trauma patients cannot benefit from these tests. In addition, it was shown that although CT scan can detect COVID-19 with higher sensitivity and specificity (2, 3, 11), it may be negative in the first few days especially in the absence of respiratory symptoms (12). The availability and early results of the lung spiral CT scan make it a more feasible diagnostic modality for the screening of asymptomatic COVID-19 infection in the ER.

The management of fracture in patients with COVID-19 infection is not straightforward. We believe that the fracture should determine the plan of treatment, at least in asymptomatic patients with COVID-19. This approach can result in earlier patient ambulation and the ability to perform self-care in isolated facilities. The conservative management of fractures may delay the patients' rehabilitation and extend the length of hospital stay. Therefore, those who provide different services for the patient would be at risk of disease transmission.

Hospitals should ensure the safety of their staff while performing operations on patients with COVID-19 (1, 13, 14). Recently, WHO has published a guideline for the use of personal protective equipment (PPE). It suggests that whenever healthcare providers have direct contact with a COVID-19 patient, they should benefit from a gown, surgical mask, gloves, and eye protection. In the case of performing aerosol-generating procedures such as endotracheal intubation, they should also use N95 or FFP2 respirators and aprons. At our patients' first visits, we were unaware of their COVID-19 which put us at risk of infection. There was also a high risk for OR personnel if the patients had undergone general anesthesia (GA), as it is an aerosol-generating procedure. The risk of infection increases when the OR staff are not aware of the patient's condition, especially in upper extremity fractures in which the routine method of anesthesia is GA. In our center, local anesthesia and nerve blocking methods are routinely used for all fractures of the upper extremity.

Conclusion

At the time of the COVID-19 epidemic, there is a substantial risk of encountering asymptomatic patients with COVID-19 who present to the ER. All emergency physicians and orthopedic surgeons need to be vigilant and use standard PPE during the evaluation of all trauma patients. The use of a lung spiral CT scan as a screening tool in the ER would be helpful in cases with suspected COVID-19 even though there is not enough evidence to support this practice.

Conflict of Interest

The authors declare no conflict of interest in this study.

Acknowledgments

None.

References

- Sohrabi C, Alsafi Z, O'Neill N, Khan M, Kerwan A, Al-Jabir A, et al. World Health Organization declares global emergency: A review of the 2019 novel coronavirus (COVID-19). *Int J Surg*. 2020;76:71-6. doi: [10.1016/j.ijsu.2020.02.034](https://doi.org/10.1016/j.ijsu.2020.02.034). [PubMed: [32112977](https://pubmed.ncbi.nlm.nih.gov/32112977/)]. [PubMed Central: [PMC7105032](https://pubmed.ncbi.nlm.nih.gov/PMC7105032/)].
- Fang Y, Zhang H, Xie J, Lin M, Ying L, Pang P, et al. Sensitivity of Chest CT for COVID-19: Comparison to RT-PCR. *Radiology*.

- 2020;296(2):E115-E117. doi: [10.1148/radiol.2020200432](https://doi.org/10.1148/radiol.2020200432). [PubMed: [32073353](https://pubmed.ncbi.nlm.nih.gov/32073353/)]. [PubMed Central: [PMC7233365](https://pubmed.ncbi.nlm.nih.gov/PMC7233365/)].
3. Ai T, Yang Z, Hou H, Zhan C, Chen C, Lv W, et al. Correlation of chest CT and RT-PCR testing for coronavirus disease 2019 (COVID-19) in China: A Report of 1014 Cases. *Radiology*. 2020;296(2):E32-E40. doi: [10.1148/radiol.2020200642](https://doi.org/10.1148/radiol.2020200642). [PubMed: [32101510](https://pubmed.ncbi.nlm.nih.gov/32101510/)]. [PubMed Central: [PMC7233399](https://pubmed.ncbi.nlm.nih.gov/PMC7233399/)].
 4. The epidemiological characteristics of an outbreak of 2019 novel coronavirus diseases (COVID-19) in China. *Zhonghua Liu Xing Bing Xue Za Zhi*. 2020;41(2):145-51. doi: [10.3760/cma.j.issn.0254-6450.2020.02.003](https://doi.org/10.3760/cma.j.issn.0254-6450.2020.02.003). [PubMed: [32064853](https://pubmed.ncbi.nlm.nih.gov/32064853/)].
 5. Rocklöv J, Sjödin H, Wilder-Smith A. COVID-19 outbreak on the Diamond Princess cruise ship: estimating the epidemic potential and effectiveness of public health countermeasures. *J Travel Med*. 2020;27(3):taaa030. doi: [10.1093/jtm/taaa030](https://doi.org/10.1093/jtm/taaa030). [PubMed: [32109273](https://pubmed.ncbi.nlm.nih.gov/32109273/)]. [PubMed Central: [PMC7107563](https://pubmed.ncbi.nlm.nih.gov/PMC7107563/)].
 6. Chan JF, Yuan S, Kok KH, To KK, Chu H, Yang J, et al. A familial cluster of pneumonia associated with the 2019 novel coronavirus indicating person-to-person transmission: A study of a family cluster. *Lancet*. 2020;395(10223):514-23. doi: [10.1016/S0140-6736\(20\)30154-9](https://doi.org/10.1016/S0140-6736(20)30154-9). [PubMed: [31986261](https://pubmed.ncbi.nlm.nih.gov/31986261/)]. [PubMed Central: [PMC7159286](https://pubmed.ncbi.nlm.nih.gov/PMC7159286/)].
 7. Liu YC, Liao CH, Chang CF, Chou CC, Lin YR. A Locally Transmitted Case of SARS-CoV-2 Infection in Taiwan. *N Engl J Med*. 2020;382(11):1070-2. doi: [10.1056/NEJMc2001573](https://doi.org/10.1056/NEJMc2001573). [PubMed: [32050059](https://pubmed.ncbi.nlm.nih.gov/32050059/)]. [PubMed Central: [PMC7121202](https://pubmed.ncbi.nlm.nih.gov/PMC7121202/)].
 8. Wang D, Hu B, Hu C, Zhu F, Liu X, Zhang J, et al. Clinical Characteristics of 138 Hospitalized Patients with 2019 Novel Coronavirus-Infected Pneumonia in Wuhan, China. *JAMA*. 2020;323(11):1061-9. doi: [10.1001/jama.2020.1585](https://doi.org/10.1001/jama.2020.1585). [PubMed: [32031570](https://pubmed.ncbi.nlm.nih.gov/32031570/)]. [PubMed Central: [PMC7042881](https://pubmed.ncbi.nlm.nih.gov/PMC7042881/)].
 9. Chan JF, Yip CC, To KK, Tang TH, Wong SC, Leung KH, et al. Improved molecular diagnosis of COVID-19 by the novel, highly sensitive and specific COVID-19-RdRp/HeI real-time reverse transcription-PCR assay validated in vitro and with clinical specimens. *J Clin Microbiol*. 2020;58(5):e00310-20. doi: [10.1128/JCM.00310-20](https://doi.org/10.1128/JCM.00310-20). [PubMed: [32132196](https://pubmed.ncbi.nlm.nih.gov/32132196/)]. [PubMed Central: [PMC7180250](https://pubmed.ncbi.nlm.nih.gov/PMC7180250/)].
 10. Li Z, Yi Y, Luo X, Xiong N, Liu Y, Li S, et al. Development and clinical application of a rapid IgM-IgG combined antibody test for SARS-CoV-2 infection diagnosis. *J Med Virol*. 2020. doi: [10.1002/jmv.25727](https://doi.org/10.1002/jmv.25727). [PubMed: [32104917](https://pubmed.ncbi.nlm.nih.gov/32104917/)]. [PubMed Central: [PMC7228300](https://pubmed.ncbi.nlm.nih.gov/PMC7228300/)].
 11. Kanne JP, Little BP, Chung JH, Elicker BM, Ketani LH. Essentials for Radiologists on COVID-19: An Update-Radiology Scientific Expert Panel. *Radiology*. 2020;296(2):E113-E114. doi: [10.1148/radiol.2020200527](https://doi.org/10.1148/radiol.2020200527). [PubMed: [32105562](https://pubmed.ncbi.nlm.nih.gov/32105562/)]. [PubMed Central: [PMC7233379](https://pubmed.ncbi.nlm.nih.gov/PMC7233379/)]. [Epub ahead of print].
 12. Yang W, Yan F. Patients with RT-PCR-confirmed COVID-19 and Normal Chest CT. *Radiology*. 2020;295(2):E3. doi: [10.1148/radiol.2020200702](https://doi.org/10.1148/radiol.2020200702). [PubMed: [32142398](https://pubmed.ncbi.nlm.nih.gov/32142398/)]. [PubMed Central: [PMC7233382](https://pubmed.ncbi.nlm.nih.gov/PMC7233382/)].
 13. Chen X, Shang Y, Yao S, Liu R, Liu H. Perioperative Care Provider's Considerations in Managing Patients with the COVID-19 Infections. *Transl Perioper & Pain Med*. 2020;7(2):216-24.
 14. Cascella M, Rajnik M, Cuomo A, Dulebohn SC, Di Napoli R. Features, Evaluation, and Treatment of Coronavirus. *StatPearls*. 2020. [PubMed: [32150360](https://pubmed.ncbi.nlm.nih.gov/32150360/)].