

# Management of the Multiply Injured Child

Mohammad Sajad Mirhoseini<sup>1</sup>, Mohsen Tavakoli<sup>1</sup>, Mina Bakhshali Bakhtiari<sup>2</sup>, Salman Azarsina<sup>1</sup>, Monir Najafi Pirasteh<sup>1</sup>, Farsad Biglari<sup>1</sup>, Arvin Najafi<sup>1</sup>, Nooshin Taherzadeh-Ghahfarokhi<sup>1,3,\*</sup>

<sup>1</sup> Assistant Professor, Department of Orthopedics, School of Medicine, Alborz University of Medical Sciences, Karaj, Iran

<sup>2</sup> General Practitioner, School of Medicine, Shahid Beheshti University of Medical Sciences, Tehran, Iran

<sup>3</sup> Student Research Committee, Alborz University of Medical Sciences, Karaj, Iran

\*Corresponding author: Nooshin Taherzadeh-Ghahfarokhi; Student Research Committee, Alborz University of Medical Sciences, Karaj, Iran. Tel: +98-9351591059, Email: [taherzadeh.nooshin@gmail.com](mailto:taherzadeh.nooshin@gmail.com)

Received: 16 December 2018; Revised: 11 February 2019; Accepted: 27 March 2019

**Keywords:** Multiple Trauma; Pediatrics; Disease Management

**Citation:** Mirhoseini MS, Tavakoli M, Bakhshali Bakhtiari M, Azarsina S, Najafi Pirasteh M, Biglari F, et al. Management of the Multiply Injured Child. *J Orthop Spine Trauma* 2019; 5(2): 37-9.



## Background

Polytrauma indicates a condition in which a patient is affected by several serious injuries. This condition can threaten life of a child. These injuries normally involve two or more crucial parts of body. Falling from height and motor accident are the two most common causes of pediatric multiple trauma. Around 30% of children with serious trauma die because of inadequate primitive assessment. To reduce the rate of mortality and morbidity, it is essential to know the primary and then the secondary survey of the patient (1).

### *The Differences between Polytrauma Injury in Pediatrics and Adults*

The outcome in pediatric group is better. It is true in pulmonary contusions, head injury, wounds and fractures healing, healing of open fracture genitourinary injuries, fat embolism, and acute respiratory distress syndrome (ARDS), and deep vein thrombosis (DVT) and pulmonary thromboembolism (PTE) are rare in patients with pediatric polytrauma (2). Greater head-body ratio, less subcutaneous fat, high body surface-to-mass ratio, and less myelinated brain make children capable of intensive head injuries (Figure 1) (3).



**Figure 1.** On average, head to body ratio in adults is about 1 to 8. On the other hands, children have relatively bigger heads, so their head to body ratio is about 1 to 4. That is one of the reasons why children are more vulnerable to head injuries.

## First Survey

The first hour (the “golden hour”) after injury is the most critical hour in influencing the rate of survival in a multiply injured child.

Initial resuscitation follows the Advanced Trauma Life Support (ATLS) or Pediatric Advanced Life Support (PALS) protocols, Airway, Breathing, Circulation, Disability (neurologic examination), Exposure (extremities and back) (ABCDE). Urinary catheter is mandatory too (4).

### Step 1. A for Airway

It is too important to make available proper airway as soon as possible in severe injuries at the site of accident. It can affect directly life or death of patient.

A specific transport board with an occipital cutout is used to transport the child under 6 years old due to large head-to-body ratio. Using traditional transport board for young children can cause cervical cord injury because of flexion of cervical spine. We can use a mattress beneath the child body in situation that special transport board is not available (Figure 2). Immobilization of the cervical spine is necessary because every multiply injured child is supposed to have cervical spine injury (4).



**Figure 2.** This picture demonstrates how to place a mattress under the child's body in case there is no special transport board to carry the multiply injured child.

### Step 2. B for Breathing

Evaluate breathing: Look for general signs of respiratory failure, count the respiratory rate, listen to the patient's breath sound, assess any chest deformity, and observe chest expansion, use of accessory muscles, and

abdominal movement (5).

### Step 3. C for Circulation

Look at the skin color, measure the limb temperature and capillary refill time (CRT), count the heart rate.

Hypovolemia is the most common cause of shock in pediatric trauma, so early and sufficient fluid resuscitation is essential. If we cannot reverse hypovolemic shock in early stage, patient may die. The infusion plan involves the rapid administration of 20 ml/kg bolus of crystalloids that can be repeated up to three times to a total of 60 ml/kg. In the case of difficult rapid intravenous (IV) access which is popular in young children, installation of a large-bore intraosseous needle into the proximal tibial metaphysis is helpful (1).

### Step 4. D for Disability

Assess patient's level of consciousness using AVPU scale (Alert, Voice, Pain, Unresponsive) (5).

### Step 5. E for Exposure

Full body exposure may be necessary in order to examine child, so it is so important to keep them warm. The first important thing that must be noticed is that the kids are not small adults, kids are different. Children body absorbs a lot of energy because they have large body surface-to-mass ratio. Greater relative body surface loses greater heat, so they are subjected to hypothermia. Hypothermia can cause detrimental acidosis and coagulopathy (triad of death) (3).

#### Second Survey

After the management of the patient in the first survey and stability of the vital signs, the team and the physician can start their second survey. Second survey includes a complete patient history and a complete and serial examination from head to foot. Ecchymosis on the abdominal wall can indicate abdominal and sometimes spine injury. Taking radiographs and other imaging according to physical exam are included in the second survey too. Taking a pelvic, chest, and bedside lateral neck radiograph is mandatory (1, 3).

#### No Orthopedic Conditions

##### Step 1. Traumatic Brain Injury (TBI)

Children have bigger heads in proportion to their body. This anatomical difference with less myelinated brain and thinner cranial bones make them more prone to head injury compared to adults (3).

TBI is the most common non-orthopedic injury in the children. Fortunately, rapid and complete recovery is expected in children, but it is the most common cause of proceeding affliction. Contracture and spasticity are common consequences and should be informed early (4).

### Step 2. Abdominal Injury

Because of the anatomical differences with adults, children are more susceptible to abdominal injury (3).

Abdominal injury includes 8% to 27% of patients with pediatric polytrauma. Injury can be missed easily in children because they have excellent physiological reserve. They can remain stable in spite of significant injuries. Therefore, the abdominal injury is the most common site of initially-unrecognized lethal injury in traumatized children. Abdominal visceral injuries may often not be appreciated until computed tomography (CT) scans are obtained in patients with polytrauma (1). Abdominal wall ecchymosis could demonstrate severe visceral or spine injury but it is not present in many children (1, 4).

### Step 3. Thoracic Injury

Thoracic injury includes 8% to 62% of patients with pediatric polytrauma.

### Step 4. Peripheral Nerve Injuries

If the nerve injury occurs at the site of an open fracture, exploration is necessary. In closed injuries, the patient must be observed.

Following serial observation and electrodiagnostic testing are mandatory if function does not return within 2 to 3 months. Surgical repair with nerve grafts may lead to functional recovery in children and adolescents in the case of peripheral nerve injury (6).

#### Orthopedic Conditions

Children recover remarkably well most of the times from what appears to be a destructive injury to the central nervous system (CNS) or other organs at first. The best orthopedic care must be undertaken consequently. Thus, early stabilization of fracture minimizes fracture complications such as pain, secondary neurovascular damage, sepsis, systemic inflammatory response syndrome (SIRS), etc. (1).

### Step 5. Extremity Fracture

Since that friction at the site of a long bone fracture results in increased ICP, it is so important to immobilize limb until definitive fracture care. Splinting or casting is often used for initial immobilization. We can also stabilize fracture with internal or external fixator. Stabilization should be done within 2 to 3 days of injury. In the setting of pediatric polytrauma, most long bone fractures are treated surgically to facilitate patient care and rehabilitation. The object of treatment is to reach union and preserve normal length of limb (Figure 3).

Percutaneous pinning of the radius is appropriate for distal forearm fractures. A short arm cast usually is used in order to maintain appropriate alignment following fixation.

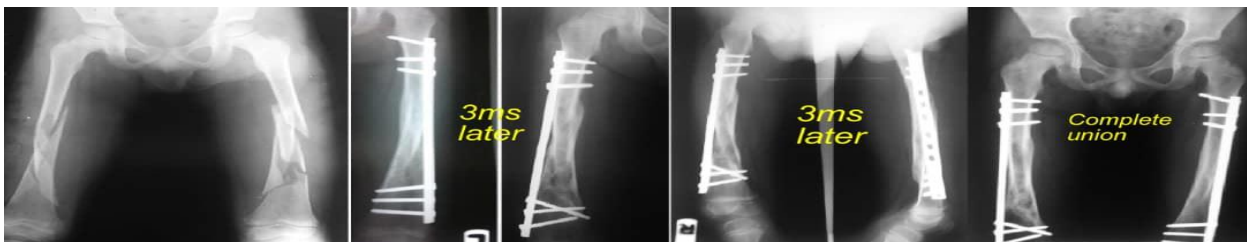


Figure 3. A 6-year-old boy with bilateral femur fractures treated by biologic plate fixation

After 3 to 4 weeks, we can remove pins, but the cast should remain for a total of 6 weeks. For femoral shaft fracture, we can use flexible intramedullary nails. For most open tibial and femoral fractures in children, flexible intramedullary rod fixation is treatment of choice. External fixation is a better choice for fractures with segmental bone loss, and ring fixators may even be used in such instances for bone transport. External fixation allows weight bearing relatively soon after the injury. A multiplanar or ring fixator is used for some segmental fractures in the metaphysis and diaphysis as well as soft tissue injuries. For fractures that involve both the metaphysis and diaphysis, open reduction and internal fixation can be combined with external fixation (4).

#### Step 6. Pelvic Fractures

62% of children with pelvic fractures have another orthopedic injury. Pelvic fracture is a high-energy injury. Surgery is not indicated in most children with pelvic fracture. Urgent external fixation or placement of a pelvic binder may be necessary in child with hemodynamic instability. Reducing fractures for reconstitution of birth canal in female patients may be necessary in the case of iliac wings displacement or changing in the pelvic ring shape (4).

#### Step 7. Amputation

Attempt should be made to preserve all extremities. The result in pediatric group is better than adults. As much limb length as possible must be preserved. This is also true for preservation of physes in young children (4).

#### Step 8. Nutrition

A child with polytrauma has a high-caloric demand and requires 150% of the basal energy or caloric requirements for age and weight. Child with ventilator support for several days needs caloric intake through enteral or parenteral supplementation to avoid catabolism (7).

#### Step 9. Antibiotic Therapy in Open Fracture

For Gustilo type I and some type II open fractures, a first-generation cephalosporin (e.g., cefazolin) 100 mg/kg/day q8h is administered (maximal daily dose is 6 g).

For severe type II and type III, cefazolin + aminoglycoside 5 to 7.5 mg/kg/day q8h is administered.

In the case of farm injuries or gross contamination, cephalosporin + aminoglycoside + penicillin 150000 units/kg/day q6h (maximal daily dose is 24 million units) is administered. In methicillin-resistant *Staphylococcus aureus* (MRSA) cases, aminoglycoside + penicillin + clindamycin or vancomycin is administered.

All antibiotics are administered intravenously, only for 24 to 72 hours. An additional 48-hour course should be given around subsequent surgeries like repeated irrigation and debridement, delayed wound closure, open reduction and internal fixation of fractures, and secondary bone reconstruction procedures (4).

#### Damage-Control Orthopedics (DCO)

DCO indicates immobilization of long bone fractures and reducing soft tissue involvement in order to minimize the risk of complications such as severe pain, fat embolism, massive hemorrhage, and multiple organ failure.

It is temporary stabilization of fractures with external fixator until the patient is systemically stable

enough to undergo definitive fracture fixation. External fixator is inserted quickly and safely in the intensive care unit (ICU) or at bedside without any fluoroscopy guide (8, 9).

These are some parameters that help us to decide who should undergo DCO: 1) Injury Severity Score (ISS) > 40 (without thoracic trauma), 2) ISS > 20 (with thoracic trauma), 3) Glasgow Coma Scale (GCS) of 8 or less, 4) multiple injuries with severe pelvic/abdominal trauma and hemorrhagic shock, 5) bilateral femoral fractures, 6) pulmonary contusion noted on radiographs, 7) hypothermia < 35 °C, 8) head injury with Abbreviated Injury Score (AIS) of 3 or more, and 9) interleukin 6 (IL-6) values above 500 pg/dl (10).

#### Conflict of Interest

The authors declare no conflict of interest in this study.

#### Acknowledgments

We wish to extend our special thanks to our colleague, dear Dr. Mohsen Tavakoli, for sharing his pearls of wisdom with us during the writing of this paper.

#### References

1. Mevius H, van Dijk M, Numanoglu A, van As AB. Article Commentary: The management of pediatric polytrauma: Review. *Clinical medicine insights: Trauma and Intensive Medicine*. 2014;5. doi: [10.4137/CMTIM.S12260](https://doi.org/10.4137/CMTIM.S12260).
2. Goedeke J, Boehm R, Dietz HG. Multiply trauma in children: Pulmonary contusion does not necessarily lead to a worsening of the treatment success. *Eur J Pediatr Surg*. 2014;24(6):508-13. doi: [10.1055/s-0033-1354583](https://doi.org/10.1055/s-0033-1354583). [PubMed: [24000128](https://pubmed.ncbi.nlm.nih.gov/24000128/)].
3. Miele V, Trinci M. Imaging non-traumatic abdominal emergencies in pediatric patients. Berlin, Germany: Springer International Publishing; 2016. p. 1-28.
4. Waters PM, Skaggs DL, Flynn JM. Rockwood and Wilkins' fractures in children. Philadelphia, PA: Lippincott Williams & Wilkins; 2019.
5. Cleugh FM, Maconochie IK. Management of the multiply injured child. *Paediatr Child Health*. 2013;23(5):194-9.
6. Kyle UG, Lucas LA, Mackey G, Silva JC, Lusk J, Orellana R, et al. Implementation of nutrition support guidelines may affect energy and protein intake in the pediatric intensive care unit. *J Acad Nutr Diet*. 2016;116(5):844-51. doi: [10.1016/j.jand.2016.01.005](https://doi.org/10.1016/j.jand.2016.01.005). [PubMed: [27126156](https://pubmed.ncbi.nlm.nih.gov/27126156/)].
7. Mooney JF. The use of 'damage control orthopedics' techniques in children with segmental open femur fractures. *J Pediatr Orthop B*. 2012;21(5):400-3. doi: [10.1097/BPB.0b013e32834fe897](https://doi.org/10.1097/BPB.0b013e32834fe897). [PubMed: [22850423](https://pubmed.ncbi.nlm.nih.gov/22850423/)].
8. Tuttle MS, Smith WR, Williams AE, Agudelo JF, Hartshorn CJ, Moore EE, et al. Safety and efficacy of damage control external fixation versus early definitive stabilization for femoral shaft fractures in the multiple-injured patient. *J Trauma*. 2009;67(3):602-5. doi: [10.1097/TA.0b013e3181aa21c0](https://doi.org/10.1097/TA.0b013e3181aa21c0). [PubMed: [19741407](https://pubmed.ncbi.nlm.nih.gov/19741407/)].
9. Allen CJ, Murray CR, Meizoso JP, Ray JJ, Neville HL, Schulman CI, et al. Risk factors for venous thromboembolism after pediatric trauma. *J Pediatr Surg*. 2016;51(1):168-71. doi: [10.1016/j.jpedsurg.2015.10.033](https://doi.org/10.1016/j.jpedsurg.2015.10.033). [PubMed: [26547285](https://pubmed.ncbi.nlm.nih.gov/26547285/)].
10. Edgington J, Szatkowski J. Evaluation, Resuscitation & DCO [Online]. [cited 2019]; Available from: URL: <https://www.orthobullets.com/trauma/1005/evaluation-resuscitation-and-dco>