

Step by Step Approach to Interpretation of Pediatric Elbow Radiography

Ehsan Hedayat¹, Nicolas Apostolou², Mohammad Aref Mohammadi³, Mohammad Hossein Nabian^{4,*}

¹ Resident, Department of Orthopedic Surgery, Shariati Hospital, School of Medicine, Tehran University of Medical Sciences, Tehran, Iran

² Hospital Practitioner, Department of Orthopedic Surgery, Centre Hospitalier Henri Duffaut, Avignon, France

³ Fellowship of Orthopedic Surgery, Department of Orthopedic Surgery, Shariati Hospital, School of Medicine, Tehran University of Medical Sciences, Tehran, Iran

⁴ Assistant Professor, Department of Orthopedic Surgery, Shariati Hospital, School of Medicine, Tehran University of Medical Sciences, Tehran, Iran

*Corresponding author: Mohammad Hossein Nabian; Department of Orthopedic Surgery, Shariati Hospital, School of Medicine, Tehran University of Medical Sciences, Tehran, Iran. Tel: +98-9126305095, Email: dr.nabian@gmail.com

Received: 15 September 2018; Revised: 05 November 2018; Accepted: 27 January 2019

Keywords: Elbow; Humeral Fractures; Pediatrics; Radiography

Citation: Hedayat E, Apostolou N, Mohammadi MA, Nabian MH. Step by Step Approach to Interpretation of Pediatric Elbow Radiography. *J Orthop Spine Trauma* 2019; 5(1): 7-11.



Background

Pediatric elbow traumas are common and may be cause of different types of injuries such as soft tissue, bony, or cartilage injuries. Fall on an outstretched hand is the most common mechanism of injury that results in hyperextension or valgus load to the elbow (1, 2).

Compared with adults, higher incidence and variability of elbow fracture patterns in pediatrics make these injuries difficult to recognize (3). Almost 70% of all pediatric fractures are related to upper extremity. Supracondylar humerus fracture is most common. The second and third common fractures are lateral humeral condyle and medial humeral epicondyle fractures (4).

Interpretation of pediatric elbow radiography needs a systematic approach to prevent misdiagnosis. In this study, we explained a six-step approach to elbow radiography for better diagnosis of the injury.

Step 1. Correct Imaging Techniques

Anteroposterior (AP) View

This view is obtained with the central beam of X-ray, positioned perpendicular to the extended elbow with supinated hand (Figure 1A). In AP view, we can assess the medial and lateral epicondyles, the radiocapitellar joint, and trochlear articular surface.

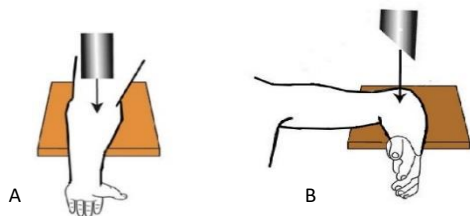


Figure 1. A: Anteroposterior (AP) view; B: Lateral view

Lateral View

This view is obtained with 90 degrees flexion of the elbow with abducted shoulder, the forearm resting on the table and thumb directed upward and the beam is centered to the radial head (Figure 1B). In lateral view, in addition to assessment of bony structures such as

olecranon, coronoid process, radial head, and the congruency of ulnohumeral joint, some evaluations of soft tissue components are also possible (2, 5).

A standard lateral radiographic view is necessary for correct judgment about distal humerus fractures. In a standard lateral view (true lateral) of distal humerus, the bony pattern shapes an hourglass-like view. It is slightly tilted forward in a true lateral view of a normal elbow (Figure 2).

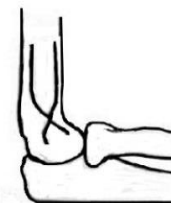

Figure 2. Hourglass sign

Step 2. Evaluating the Ossification Centers

Bony template of the pediatric elbow shows growth in a predictable and physiologic pattern. Understanding the timing of this developmental sequence in radiography lets us differentiate between subtle fractures and normal variations.

The process of ossification begins at diaphysis of long bones such as humerus, radius, and ulna and progresses to proximal and distal ends (Figure 3). Ossification of the humerus extends to the condyles, the ulna extends to interval between the coronoid process and the tip of the olecranon, the radius ossifies proximally to the neck (Table 1) (7).

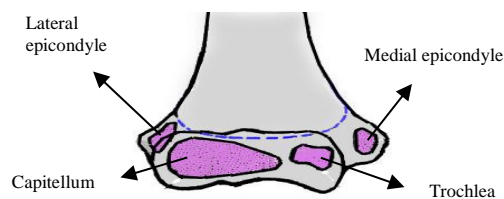


Figure 3. Distal humerus ossification centers

Table 1. Timing of appearance of elbow ossification centers

	Girls (year)	Boys (year)
Capitellum	1.0	1.0
Radial head	5.0	6.0
Medial epicondyle	5.0	7.5
Olecranon	8.7	10.5
Trochlea	9.0	10.7
Lateral epicondyle	10.0	12.0

Step 3. Evaluating Joint Effusion and Soft Tissue Swelling

Anterior and posterior fat pads lie on the proximal end of the anterior (coronoid fossa) and posterior (olecranon fossa) capsule of elbow joint (Figure 4). Intracapsular fractures cause hemarthrosis which results in a gap between capsule and distal end of humerus. We name it posterior and anterior fat pad signs.

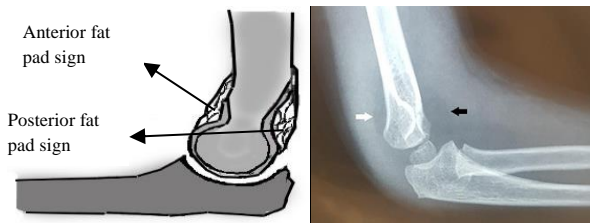


Figure 4. Anterior (black arrow) and posterior (white arrow) fat pad signs

Step 4. Evaluation of Alignment

Teardrop

In lateral view above the capitellum, the bony pattern of distal humerus shapes like a teardrop (Figure 5) (8). Posterior margin of coronoid fossa makes anterior line of teardrop. The anterior border of the olecranon fossa makes posterior line of teardrop. Ossification center of capitellum shapes inferior part of teardrop. On a true lateral view, teardrop should be well seen.

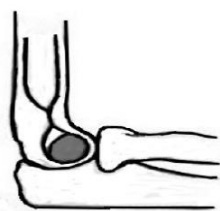

Figure 5. Teardrop

Shaft-Condylar Angle

Shaft condylar angle is between long axis of humeral shaft and long axis of lateral condyle in true lateral radiograph (Figure 6). Normal angle range is around 40 degrees (9).

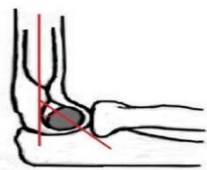

Figure 6. Shaft-condylar angle

Anterior Humeral Line

Anterior humeral line is a tangential line to anterior cortex of the distal shaft of humerus; it must cross with ossification center of the capitellum in the middle third (Figure 7). Passing from anterior or posterior of it, means distal humerus fracture (10). Rogers et al. in patients with minimally-displaced supracondylar humeral fractures found that anterior humeral line was the best factor in reliability to detecting occult fractures (4).

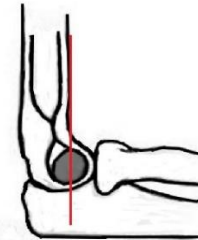


Figure 7. Anterior humeral line

Coronoid Line

Coronoid line is a tangential line to anterior border of coronoid process. Proximally, it should touch the anterior cortex of lateral humeral condyle (Figure 8). Posterior position of ossification center of lateral humeral condyle relative to coronoid line means posterior angulation of the condyle (8).

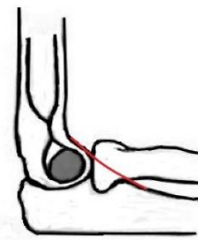

Figure 8. Coronoid line

Humeral-Ulnar Angle

The angle between long axis of humeral shaft and ulnar shaft in AP view, the humeral-ulnar angle (Figure 9), is the best way (most accurate) to define the carrying angle of the elbow. Normal carrying angle ranges from 0° to 25° (11, 12).

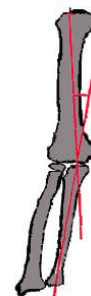

Figure 9. Humeral-ulnar angle

Metaphyseal-Diaphyseal Angle

Same as humeral-ulnar angle, it is measured to determine the appropriate alignment of the distal humerus and carrying angle. The metaphyseal-diaphyseal angle is determined by measuring the angle between long axis of humeral shaft and the line that connects the widest

area of the metaphysis of the distal humerus (Figure 10) (13). It is useful for comparison of the injured elbow with the other side.

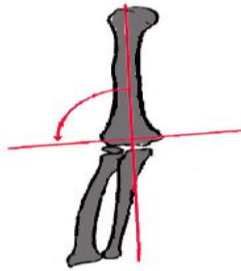


Figure 10. Metaphyseal-diaphyseal angle

Radio-Capitellar Line

Radio-capitellar line is a straight line passing through the center of the radial neck and head. In normal elbow, it passes through the center of ossification center of capitellum in all degrees of elbow flexion in lateral radiograph view (Figure 11) (14).

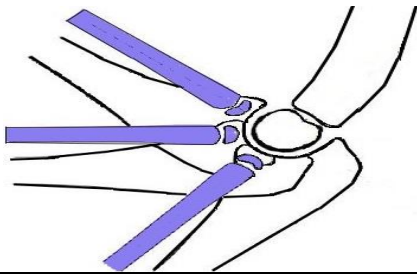


Figure 11. Radio-capitellar line must pass through the middle of the capitellum in each degree of flexion of the elbow

Baumann's Angle

In standard AP view, the angle between the inclination of the physis of capitulum and the long axis of humeral shaft is the Baumann's angle (Figure 12) (15). We can use this angle to compare the injured elbow with the other side. In standard AP radiograph of the distal humerus and Jones views, the Baumann's angle is a good criterion for evaluating the angulation of distal humerus (16).

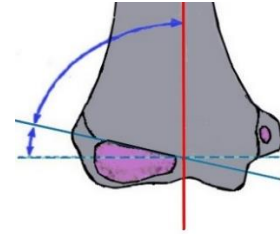


Figure 12. Baumann's angle

Lateral HumeroCapitellar Angle

As shown in figure 12, the angle between the humeral shaft and capitellar physis in standard lateral view is lateral humeroCapitellar angle (LHCA). The normal amount of LHCA is almost 51 degrees and is not affected by age, sex, or side (17).

The correlation between the LHCA and clinical outcome is unclear. Some studies reported a significant correlation between the LHCA and loss of elbow flexion (18).

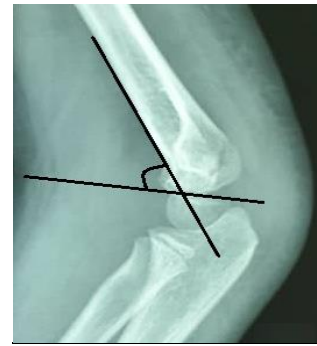

Figure 12. Lateral humeroCapitellar angle

Step 5. Evaluating the Bone Cortices

Exactly check the distal humerus, proximal ulna, and radius cortices for subtle injuries and minimally-displaced fractures. Because of incomplete ossification of pediatric distal humerus, we can judge and diagnose the fracture according to the orientation of fracture line. The following algorithm (Figure 13) may help us to better diagnose the fractures of distal humerus.

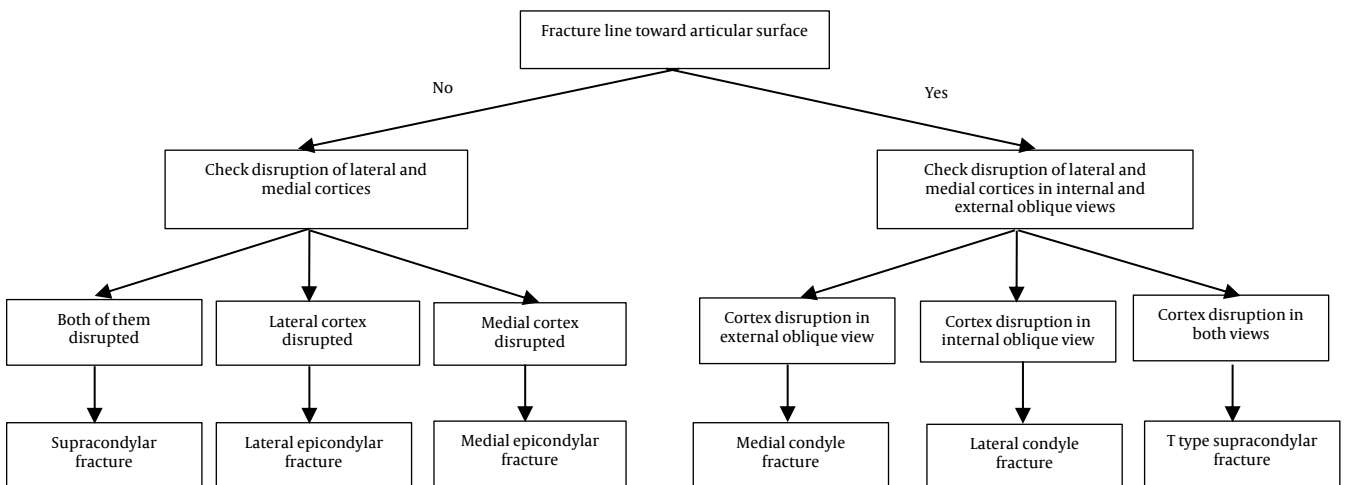


Figure 13. How to diagnose distal humeral fractures in pediatric elbow injuries

Step 6. Avoiding Common Mistakes

There are some normal radiographic findings that may mimic disease.

The presence or irregularity of some ossification centers may be mistaken for a fracture. For example, irregularity of trochlea ossification center may produce a fragmented particle shape (Figure 14) (19).

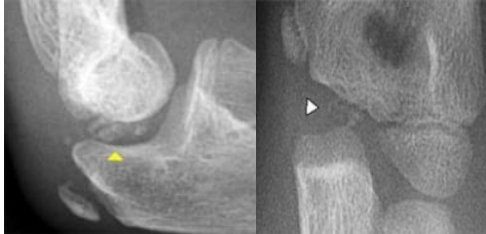

Figure 14. Irregularity of trochlea ossification center

The ossification center of olecranon process may appear like a separate nucleus (Figure 15), it is not a fracture (20).

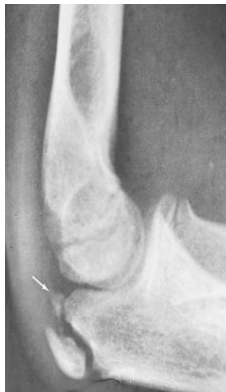

Figure 15. Fracture-like olecranon ossification center

At 3-4 years, the metaphysis of the radial neck may show a notch defect at the lateral cortex that may be mistaken with a fracture (Figure 16) (19).

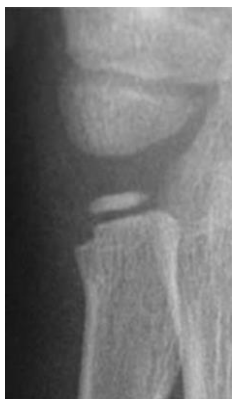

Figure 16. Notch-shaped defect in radial neck

On lateral X-ray view, radial tuberosity appears as an ovoid radiolucent lesion (Figure 17). To avoid this pitfall, one must review additional views (21).

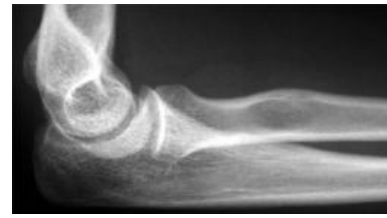

Figure 17. Fracture-like olecranon ossification center

Be careful about double injuries, for example, medial epicondyle fracture along with olecranon fracture (Figure 18).

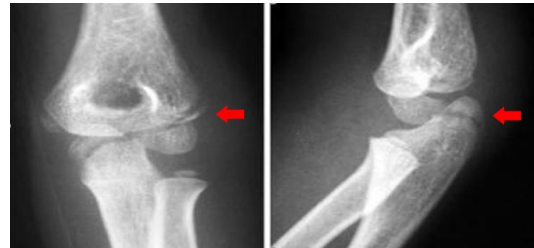

Figure 18. Double injuries; lateral condyle fracture with olecranon fracture

Other injuries may be associated with elbow trauma, e.g., elbow injury associated with distal radius fracture (Figure 19).

For better interpretation, sometimes, it is very helpful to compare the affected side with the contralateral side radiograph.

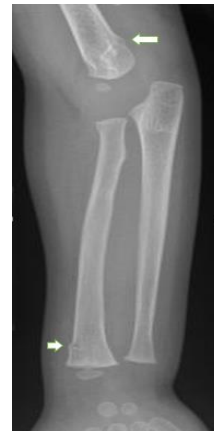

Figure 19. Associated injury; supracondylar fracture with distal radius fracture

Conclusion

Pediatric elbow x-ray radiography interpretation needs a systematic approach to prevent misdiagnosis, due to complexity of this joint. In this paper, a stepwise approach was designed to facilitate diagnosis of the injuries and prevent common mistakes (Figure 20).

Conflict of Interest

The authors declare no conflict of interest in this study.

Acknowledgments

None.

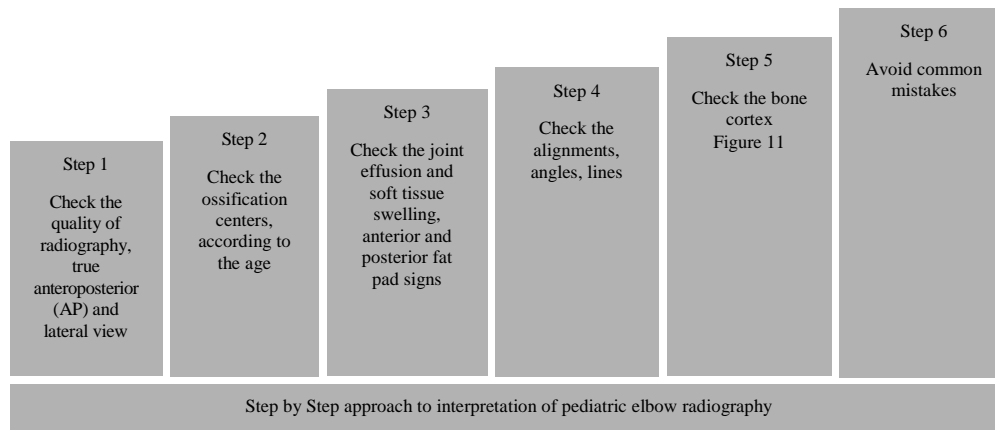


Figure 20. A stepwise approach to pediatric elbow x-ray radiography

References

- Manaster BJ, May DA, Disler DG. Musculoskeletal imaging: The requisites. Philadelphia, PA: Elsevier Health Sciences; 2013.
- Jacoby SM, Herman MJ, Morrison WB, Osterman AL. Pediatric elbow trauma: An orthopaedic perspective on the importance of radiographic interpretation. *Semin Musculoskelet Radiol.* 2007;11(1):48-56. doi: [10.1055/s-2007-984412](https://doi.org/10.1055/s-2007-984412). [PubMed: [17665350](https://pubmed.ncbi.nlm.nih.gov/17665350/)].
- Woods GW, Tullos HS. Elbow instability and medial epicondyle fractures. *Am J Sports Med.* 1977;5(1):23-30. doi: [10.1177/036354657700500105](https://doi.org/10.1177/036354657700500105). [PubMed: [848632](https://pubmed.ncbi.nlm.nih.gov/848632/)].
- Rogers LF, Malave S Jr, White H, Tachdjian MO. Plastic bowing, torus and greenstick supracondylar fractures of the humerus: Radiographic clues to obscure fractures of the elbow in children. *Radiology.* 1978;128(1):145-50. doi: [10.1148/128.1.145](https://doi.org/10.1148/128.1.145). [PubMed: [663200](https://pubmed.ncbi.nlm.nih.gov/663200/)].
- Chin TY, Chou H, Peh WCG. The acutely injured elbow. *Radiol Clin North Am.* 2019;57(5):911-30. doi: [10.1016/j.rcl.2019.03.006](https://doi.org/10.1016/j.rcl.2019.03.006). [PubMed: [31351541](https://pubmed.ncbi.nlm.nih.gov/31351541/)].
- Crosby NE, Greenberg JA. Radiographic evaluation of the elbow. *J Hand Surg Am.* 2014;39(7):1408-14. doi: [10.1016/j.jhsa.2014.04.035](https://doi.org/10.1016/j.jhsa.2014.04.035). [PubMed: [24888528](https://pubmed.ncbi.nlm.nih.gov/24888528/)].
- Docherty MA, Schwab RA, Ma OJ. Can elbow extension be used as a test of clinically significant injury? *South Med J.* 2002;95(5): 539-41. [PubMed: [12005013](https://pubmed.ncbi.nlm.nih.gov/12005013/)].
- Lennon RI, Riyat MS, Hilliam R, Anathkrishnan G, Alderson G. Can a normal range of elbow movement predict a normal elbow x ray? *Emerg Med J.* 2007;24(2):86-8. doi: [10.1136/emj.2006.039792](https://doi.org/10.1136/emj.2006.039792). [PubMed: [17251609](https://pubmed.ncbi.nlm.nih.gov/17251609/)]. [PubMed Central: [PMC2658213](https://pubmed.ncbi.nlm.nih.gov/PMC2658213/)].
- Lamprakis A, Vlasik K, Siampou E, Grammatikopoulos I, Lionis C. Can elbow-extension test be used as an alternative to radiographs in primary care? *Eur J Gen Pract.* 2007;13(4):221-4. doi: [10.1080/13814780701814820](https://doi.org/10.1080/13814780701814820). [PubMed: [18324503](https://pubmed.ncbi.nlm.nih.gov/18324503/)].
- Herman MJ, Boardman MJ, Hoover JR, Chafetz RS. Relationship of the anterior humeral line to the capitellar ossific nucleus: variability with age. *J Bone Joint Surg Am.* 2009;91(9):2188-93. doi: [10.2106/JBJS.H.01316](https://doi.org/10.2106/JBJS.H.01316). [PubMed: [19723996](https://pubmed.ncbi.nlm.nih.gov/19723996/)].
- Atrey A, Nicolaou N, Katchburian M, Norman-Taylor F. A review of reported litigation against English health trusts for the treatment of children in orthopaedics: Present trends and suggestions to reduce mistakes. *J Child Orthop.* 2010;4(5):471-6. doi: [10.1007/s11832-010-0276-4](https://doi.org/10.1007/s11832-010-0276-4). [PubMed: [21966313](https://pubmed.ncbi.nlm.nih.gov/21966313/)]. [PubMed Central: [PMC2946528](https://pubmed.ncbi.nlm.nih.gov/PMC2946528/)].
- Moraleda L, Valencia M, Barco R, Gonzalez-Moran G. Natural history of unreduced Gartland type-II supracondylar fractures of the humerus in children: A two to thirteen-year follow-up study. *J Bone Joint Surg Am.* 2013;95(1):28-34. doi: [10.2106/jbjs.l.00132](https://doi.org/10.2106/jbjs.l.00132). [PubMed: [23405411](https://pubmed.ncbi.nlm.nih.gov/23405411/)].
- Jenkins FA Jr. The functional anatomy and evolution of the mammalian humero-ulnar articulation. *Am J Anat.* 1973;137(3): 281-97. doi: [10.1002/aja.1001370304](https://doi.org/10.1002/aja.1001370304). [PubMed: [4716355](https://pubmed.ncbi.nlm.nih.gov/4716355/)].
- Storen G. Traumatic dislocation of the radial head as an isolated lesion in children; report of one case with special regard to roentgen diagnosis. *Acta Chir Scand.* 1959;116(2):144-7. [PubMed: [13626463](https://pubmed.ncbi.nlm.nih.gov/13626463/)].
- Baumann E. Beitrage zur Kenntnis der Fracturen am Ellbogengelenk. *Bruns Beitr F Klin Chir.* 1929;146:1-50.
- Silva M, Pandarinath R, Farng E, Park S, Caneda C, Fong YJ, et al. Inter- and intra-observer reliability of the Baumann angle of the humerus in children with supracondylar humeral fractures. *Int Orthop.* 2010;34(4):553-7. doi: [10.1007/s00264-009-0787-0](https://doi.org/10.1007/s00264-009-0787-0). [PubMed: [19424695](https://pubmed.ncbi.nlm.nih.gov/19424695/)]. [PubMed Central: [PMC2903132](https://pubmed.ncbi.nlm.nih.gov/PMC2903132/)].
- Shank CF, Wiater BP, Pace JL, Jinguji TM, Schmale GA, Bittner RC, et al. The lateral capitelloumbral angle in normal children: Mean, variation, and reliability in comparison to Baumann's angle. *J Pediatr Orthop.* 2011;31(3):266-71. doi: [10.1097/BPO.0b013e31821009af](https://doi.org/10.1097/BPO.0b013e31821009af). [PubMed: [21415685](https://pubmed.ncbi.nlm.nih.gov/21415685/)].
- Simanovsky N, Lamdan R, Hiller N, Simanovsky N. The measurements and standardization of humerocondylar angle in children. *J Pediatr Orthop.* 2008;28(4):463-5. doi: [10.1097/BPO.0b013e31817445ff](https://doi.org/10.1097/BPO.0b013e31817445ff). [PubMed: [18520285](https://pubmed.ncbi.nlm.nih.gov/18520285/)].
- De Boeck H. Radiology of the elbow in children. *Acta Orthop Belg.* 1996;62(Suppl 1):34-40. [PubMed: [9084558](https://pubmed.ncbi.nlm.nih.gov/9084558/)].
- Silberstein MJ, Brodeur AE, Graviss ER, Luisiri A. Some vagaries of the olecranon. *J Bone Joint Surg Am.* 1981;63(5):722-5. [PubMed: [7240295](https://pubmed.ncbi.nlm.nih.gov/7240295/)].
- Mhuircheartaigh JN, Lin YC, Wu JS. Bone tumor mimickers: A pictorial essay. *Indian J Radiol Imaging.* 2014;24(3):225-36. doi: [10.4103/0971-3026.137026](https://doi.org/10.4103/0971-3026.137026). [PubMed: [25114385](https://pubmed.ncbi.nlm.nih.gov/25114385/)]. [PubMed Central: [PMC4126137](https://pubmed.ncbi.nlm.nih.gov/PMC4126137/)].