

Flexion-Type Supracondylar Humerus Fracture: A Review on Reduction Techniques

Mohammadhasan Sharafi¹, Ana Presedo², Hamid Rabie¹, Mohammad Hossein Nabian^{3,*}

¹ Resident, Department of Orthopedic Surgery, Shariati Hospital, School of Medicine, Tehran University of Medical Sciences, Tehran, Iran

² Neuro-Orthopedic and Gait Analysis Coordinator, Department of Pediatric Orthopedics, Robert Debre University Hospital, Paris, France

³ Assistant Professor, Department of Orthopedic Surgery, Shariati Hospital, School of Medicine, Tehran University of Medical Sciences, Tehran, Iran

*Corresponding author: Mohammad Hossein Nabian; Department of Orthopedic Surgery, Shariati Hospital, School of Medicine, Tehran University of Medical Sciences, Tehran, Iran. Tel: +98-9126305095, Email: dr.nabian@gmail.com

Received: 15 March 2018; Revised: 05 June 2018; Accepted: 24 July 2018

Keywords: Humerus; Elbow; Fracture

Citation: Sharafi M, Presedo A, Rabie H, Nabian MH. Flexion-Type Supracondylar Humerus Fracture: A Review on Reduction Techniques. *J Orthop Spine Trauma* 2018; 4(3): 54-8.



Background

Supracondylar humerus fractures (SCHF) are the most common elbow fractures in children which usually need surgical treatment (1). It is mostly seen in the ages between 5 to 6 years old (2). Classically, these fractures are classified into two types, flexion and extension, based on the direction of displacement of the distal fragment.

These two types differ in many factors specially mechanism of injury and subsequently the maneuver for reduction based on fracture displacement (3). In addition, associated injuries, especially nerve injuries, differ between these two types. In flexion-type injury, ulnar nerve is at risk and careful examination and documentation is important before and after the reduction (4).

In extension-type fracture, which includes 92% to 98% of SCHF, a fall on an out-stretched hand is the mechanism of injury but in the flexion-type, a fall directly onto the elbow in flexion position is the mechanism (5) (Figure 1).

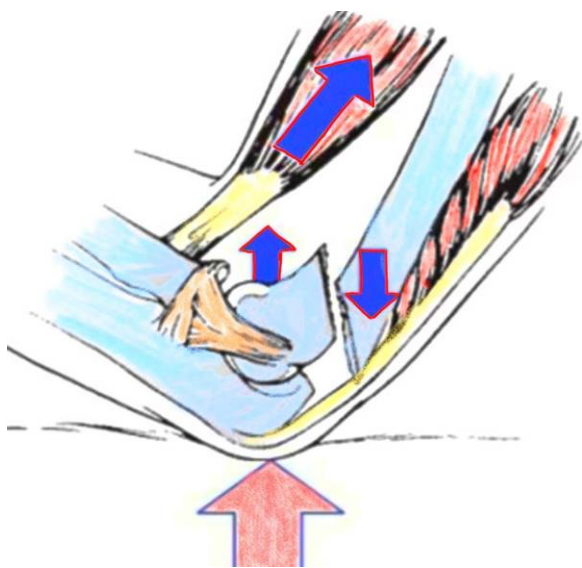


Figure 1. Mechanism of injury for flexion-type supracondylar fracture

Supracondylar fractures, especially flexion-type, are inherently unstable. Treatment of flexion-type fracture is one of the challenges in pediatric orthopedics and because of its lower prevalence, a few studies on the maneuver for reduction and fixation are available (6). Its lower prevalence, less experience of surgeons in reduction maneuvers, and higher rate of complications make it an important issue in pediatric fractures. This paper is a review on reduction techniques of flexion-type SCHF.

Radiologic Landmarks for Reduction

First step in reduction and fixation of any fracture in any bone is to know the normal anatomy of the bone, so it can be restored. In elbow bony anatomy, there are many landmarks which are keystones of reduction and normal anatomy of these landmarks should be restored.

Olecranon Fossa

In normal anteroposterior (AP) view of elbow, it appears elliptically with smooth borders (Figure 2).

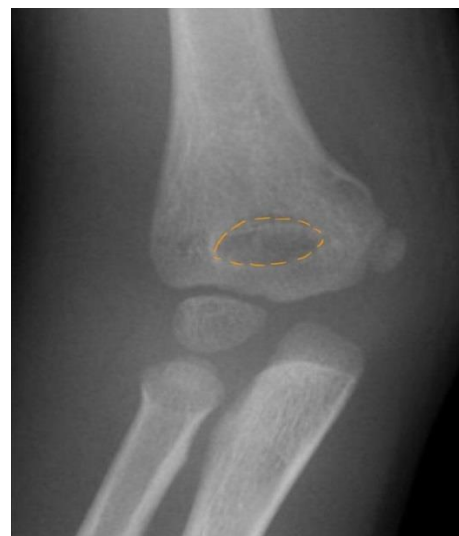

Figure 2. Normal shape of olecranon fossa

Medial and Lateral Column

Both medial and lateral columns should be aligned with no break in their continuity (7) (Figure 3).

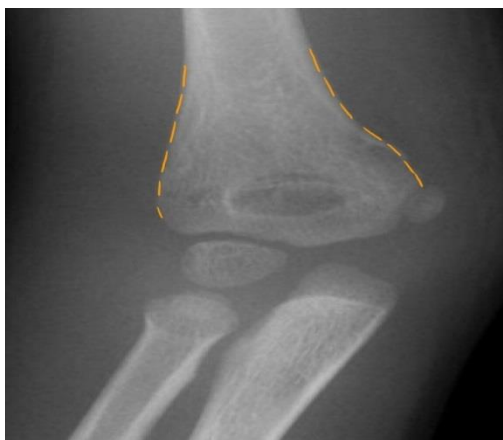

Figure 3. Medial and lateral columns of distal humerus

Any mismatch between proximal and distal fragment is unacceptable and columns and their borders should be fully matched and congruent (Figure 4).

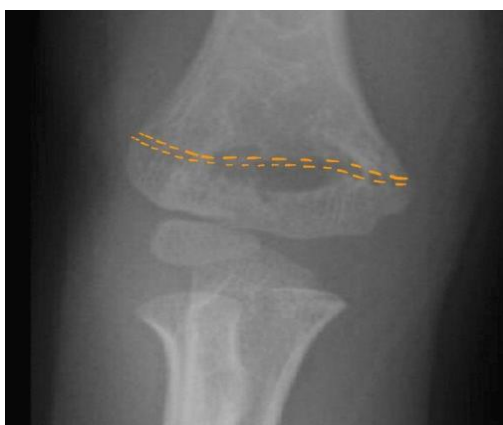

Figure 4. Congruency of fracture line in distal and proximal fragment

Hourglass View

In true lateral view of distal portion of humerus, if there is no angular and rotational malreduction, an hourglass view should be visible and it is a critical landmark for checking reduction (8) (Figure 5).

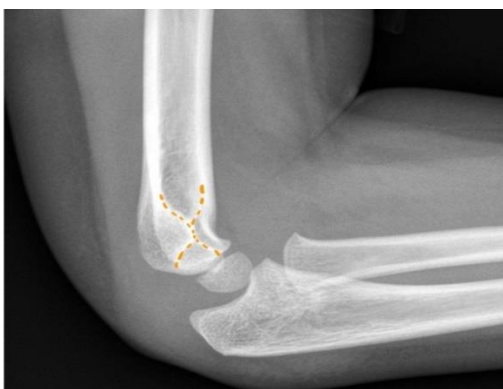

Figure 5. Note the hourglass view in true lateral x-ray of distal humerus

Anterior Humeral Line (AHL)

In lateral view, a line down on the anterior cortex of distal humerus should intersect the capitellum (9) (Figure 6).

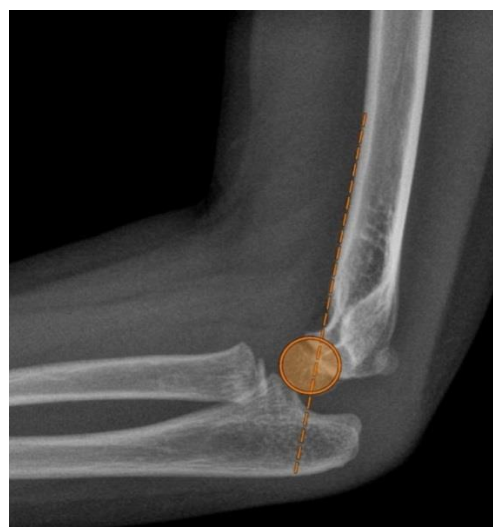

Figure 6. Anterior humeral line (AHL)

Capitellar Diameter

In early childhood, a method to check the rotational alignment is to determine the size of capitellum and the humeral shaft in the lateral view. Diameter of a circle that surrounds the capitellum should be equal to the diameter of humeral shaft (10) (Figure 7).

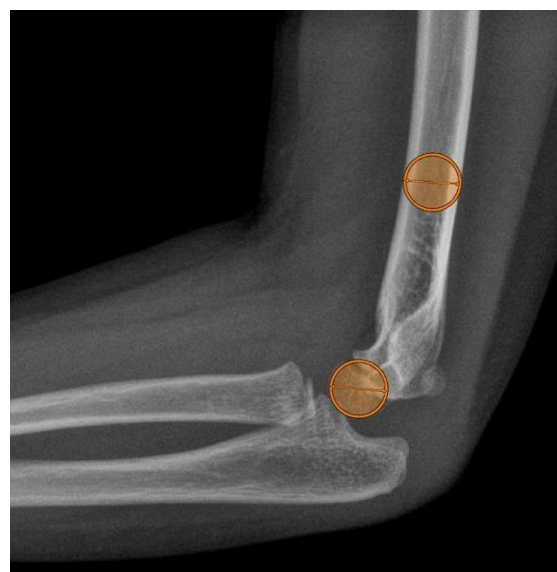

Figure 7. Correlation between capitellar and humeral shaft diameter

Fracture Line Length

In lateral view, fracture line length in proximal and distal fragment should be equal and lines should be congruent (10) (Figure 8).

Capitulum Angle

The angle between the axis of humeral shaft and the capitellum in normal elbow is between 25 to 30 degrees. Any change in this angle is an indicative for malalignment (11) (Figure 9).

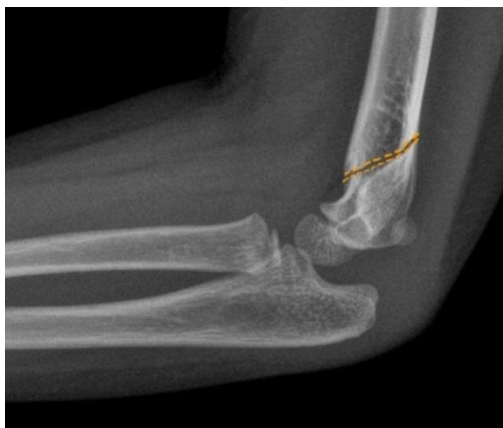

Figure 8. Fracture line length

Arbeitsgemeinschaft für Osteosynthesefragen (AO) Technique

The patient should be in supine position, in 10 degrees of elbow flexion; the arm is placed on the image intensifier, which is perpendicular to the operation table. While the assistant applies continuous traction for 4 to 5 minutes by pulling the arm, the surgeon takes the control of wrist and forearm.

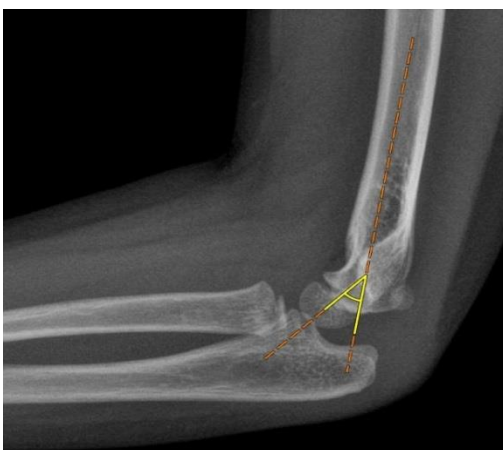

Figure 9. Capitulum-humeral angle

Traction should be gentle and without any forceful or sudden movement to avoid excessive soft tissue damage or instability of fracture (Figure 10).

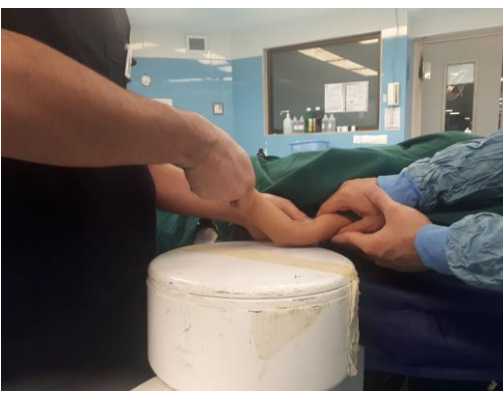

Figure 10. Longitudinal traction

Now, the surgeon while continuing the traction by non-dominant hand, moves the elbow to extension by other hand and applies direct force to the distal fragment and manipulates it to achieve reduction (Figure 11).

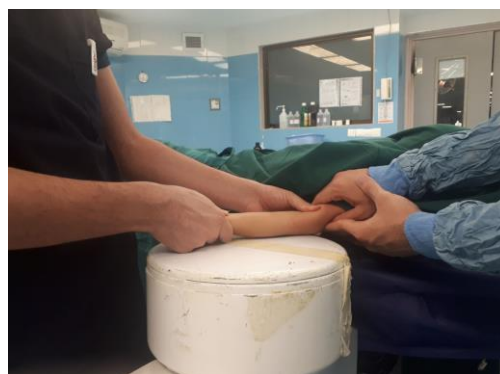

Figure 11. Correction of flexion deformity of distal fragment

Once the fracture is reduced, while the surgeon holds pressure on distal fragment, elbow should be flexed up to 90 degrees (Figure 12).

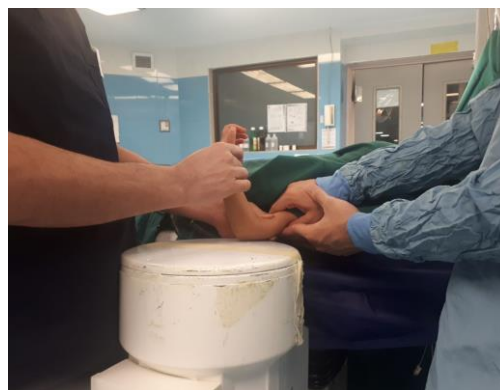

Figure 12. Flexing the elbow

Now a lateral view X-ray is obtained and quality of reduction is checked again. If reduction is acceptable, internal fixation with K-wires must be done.

If reduction is not acceptable, this maneuver can be repeated. If fracture is displaced, reduction can be done with use of a K-wire as a joystick.

keep in mind that in this technique, obtaining an AP view is easy but to obtain a lateral view, rotating the image intensifier should be done (10).

Prone Technique

In this technique, under general anesthesia, patient must be in prone position. Special attention must be paid to airway protection and keep in mind that this maneuver is not preferred for patients with abdominal or thoracic trauma.

While the anterior aspect of arm is supported by radiolucent pillow, the forearm is suspended from the table in 45 degrees flexion. Image intensifier must be placed parallel to the bed to facilitate obtaining AP and lateral views (Figure 13).

Mediolateral translation is the first parameter of fracture that must be addressed. For this purpose, the surgeon manipulates the fragment gently under the guide of image intensifier. While gentle traction is applied,

elbow must be extended gradually (Figure 14).

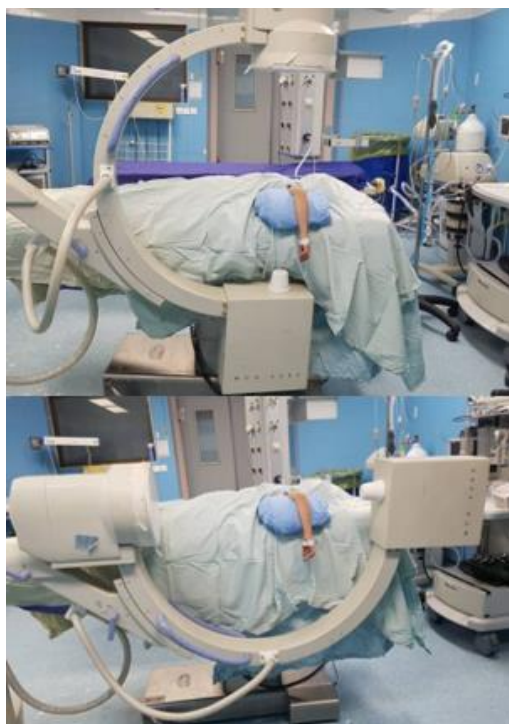

Figure 13. Positioning of the patient and image intensifier

Push-pull method

This method is done in supine position. Limb is placed on a radiolucent table, a radiolucent roll is placed under the fracture site, and image intensifier is parallel to the operating bed. While the elbow is flexed to 45 degrees, reduction in coronal plane is achieved by applying varus or valgus forces. Now, the assistant holds the arm and applies gentle traction and the surgeon simultaneously maintains the reduction in coronal plane and flexes the elbow from 45 degrees to 90 degrees.

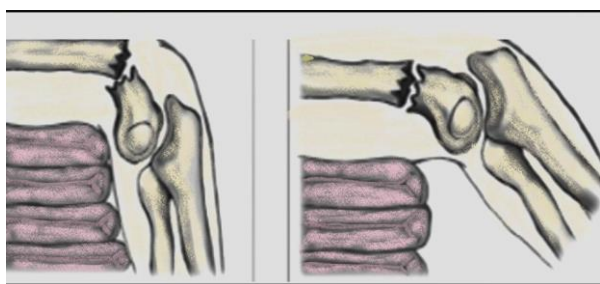


Figure 14. Correction of flexion deformity

When anatomic reduction is achieved, fixation with 2 or 3 K-wires is done (12).

Now, the image intensifier must be prepared for taking lateral views. To reduce the fracture in sagittal plane, axial force is applied to the distal fragment by pushing the forearm toward the floor, while the arm is held in position by the assistant. In this step, to determine the quality of reduction, the AHL must be checked and if it crosses the capitellum, alignment is acceptable. In cases that overcorrection has been

occurred, it must be corrected by pulling the forearm in longitudinal axis distally to achieve the perfect reduction (13) (Figure 15).

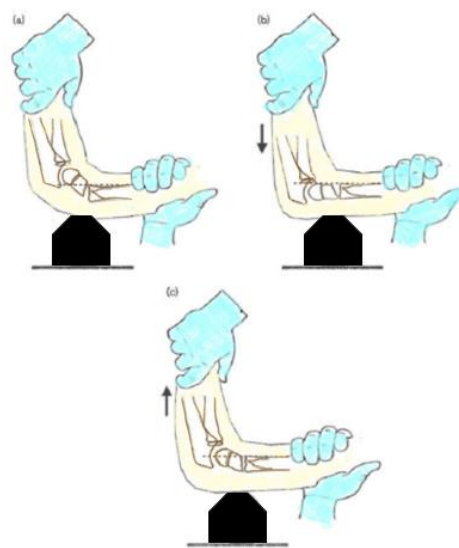


Figure 15. Push-pull method

Conflict of Interest

The authors declare no conflict of interest in this study.

Acknowledgments

None

References

- Houshian S, Mehdi B, Larsen MS. The epidemiology of elbow fracture in children: Analysis of 355 fractures, with special reference to supracondylar humerus fractures. *J Orthop Sci.* 2001;6(4):312-5. doi: [10.1007/s007760100024](https://doi.org/10.1007/s007760100024). [PubMed: [11479758](https://pubmed.ncbi.nlm.nih.gov/11479758/)].
- Cheng JC, Lam TP, Maffulli N. Epidemiological features of supracondylar fractures of the humerus in Chinese children. *J Pediatr Orthop B.* 2001;10(1):63-7. [PubMed: [11269814](https://pubmed.ncbi.nlm.nih.gov/11269814/)].
- Barr LV. Paediatric supracondylar humeral fractures: Epidemiology, mechanisms and incidence during school holidays. *J Child Orthop.* 2014;8(2):167-70. doi: [10.1007/s11832-014-0577-0](https://doi.org/10.1007/s11832-014-0577-0). [PubMed: [24643672](https://pubmed.ncbi.nlm.nih.gov/24643672/)]. [PubMed Central: [PMC3965762](https://pubmed.ncbi.nlm.nih.gov/PMC3965762/)].
- Mahan ST, May CD, Kocher MS. Operative management of displaced flexion supracondylar humerus fractures in children. *J Pediatr Orthop.* 2007;27(5):551-6. doi: [10.1097/01.bpb.0000279032.04892.6c](https://doi.org/10.1097/01.bpb.0000279032.04892.6c). [PubMed: [17585266](https://pubmed.ncbi.nlm.nih.gov/17585266/)].
- Pirwani M, Memon A, Memon F. Gartland's Type III supra condylar fracture humerus in children treated with open reduction and internal fixation with cross K-wire fixation: A prospective study. *J Liaquat Uni Med Health Sci.* 2015;14(1):33-7.
- Garg B, Pankaj A, Malhotra R, Bhan S. Treatment of flexion-type supracondylar humeral fracture in children. *J Orthop Surg (Hong Kong).* 2007;15(2):174-6. doi: [10.1177/230949900701500210](https://doi.org/10.1177/230949900701500210). [PubMed: [17709856](https://pubmed.ncbi.nlm.nih.gov/17709856/)].
- Tolo VT, Skaggs DL. *Masters techniques in pediatric orthopaedic Surgery: Pediatrics.* Philadelphia, PA: Lippincott Williams & Wilkins Company; 2015.
- DeFroda SF, Hansen H, Gil JA, Hawari AH, Cruz AI Jr. Radiographic evaluation of common pediatric elbow injuries. *Orthop Rev*

- (Pavia). 2017;9(1):7030. doi: [10.4081/or.2017.7030](https://doi.org/10.4081/or.2017.7030). [PubMed: [28286625](https://pubmed.ncbi.nlm.nih.gov/28286625/)], [PubMed Central: [PMC5337779](https://pubmed.ncbi.nlm.nih.gov/PMC5337779/)].
9. Abzug JM, Herman MJ. Management of supracondylar humerus fractures in children: Current concepts. *J Am Acad Orthop Surg*. 2012;20(2):69-77. doi: [10.5435/JAAOS-20-02-069](https://doi.org/10.5435/JAAOS-20-02-069). [PubMed: [22302444](https://pubmed.ncbi.nlm.nih.gov/22302444/)].
 10. Nambiar M, West LR, Bingham R. AO Surgery Reference: A comprehensive guide for management of fractures. *Br J Sports Med*. 2017;51(6):545. doi: [10.1136/bjsports-2016-096677](https://doi.org/10.1136/bjsports-2016-096677).
 11. Rogers LF, Malave S Jr, White H, Tachdjian MO. Plastic bowing, torus and greenstick supracondylar fractures of the humerus: Radiographic clues to obscure fractures of the elbow in children. *Radiology*. 1978;128(1):145-50. doi: [10.1148/128.1.145](https://doi.org/10.1148/128.1.145). [PubMed: [663200](https://pubmed.ncbi.nlm.nih.gov/663200/)].
 12. Kao HK, Lee WC, Yang WE, Chang CH. Treatment of displaced flexion-type pediatric supracondylar humeral fractures in the prone position. *J Orthop Surg (Hong Kong)*. 2017;25(1):2309499016684412. doi: [10.1177/2309499016684412](https://doi.org/10.1177/2309499016684412). [PubMed: [29185384](https://pubmed.ncbi.nlm.nih.gov/29185384/)].
 13. Chukwunyerewa C, Orlik B, El-Hawary R, Logan K, Howard JJ. Treatment of flexion-type supracondylar fractures in children: The 'push-pull' method for closed reduction and percutaneous K-wire fixation. *J Pediatr Orthop B*. 2016;25(5):412-6. doi: [10.1097/BPB.0000000000000241](https://doi.org/10.1097/BPB.0000000000000241). [PubMed: [26517762](https://pubmed.ncbi.nlm.nih.gov/26517762/)].